

Clinical significance and expression of the PRSS3 and Wiskott–Aldrich syndrome protein family verprolin-homologous protein 1 for the early detection of epithelial ovarian cancer

Sima Azizmohammadi¹ · Aghdas Safari² · Mehri Seifoleslami³ ·
Rahman Ghaffarzadegan Rabati⁴ · Mohsen Mohammadi⁵ · Hamid Yahaghi⁶ ·
Susan Azizmohammadi¹

Received: 16 November 2015 / Accepted: 2 December 2015
© International Society of Oncology and BioMarkers (ISOBM) 2015

Abstract In this study, we evaluate the clinical significance of the PRSS3 and Wiskott–Aldrich syndrome protein family verprolin-homologous protein 1 (WAVE1) in patients with epithelial ovarian cancer (EOC) by immunohistochemistry.

In current study, all adjacent non-cancerous tissues showed absent or low expression of PRSS3. The expression of PRSS3 was significantly increased in the EOCs than adjacent non-cancerous tissues. Moreover, the expression of WAVE1 was significantly observed in all EOC tissues when compared with normal tissues. Furthermore, WAVE1 expression was absent in 35 (89.74 %) adjacent non-cancerous tissues.

Our findings showed that high expression of PRSS3 was markedly linked to FIGO stage ($P=0.02$), advanced grade ($P=0.017$), and lymph node metastases ($P=0.001$), but no relationship was determined with other clinicopathological parameters. Furthermore, high expression of WAVE1 was

significantly correlated with FIGO stage ($P=0.001$), grade of tumor ($P=0.011$), and residual tumor size ($P=0.041$), but no significant associations were found between WAVE1 expression and age, lymph node metastasis, and histological subtypes (all $P>0.05$). In conclusion, our study showed that increased expression of PRSS3 and WAVE1 may be involved in development of EOC.

Keywords Epithelial ovarian cancer · PRSS3 · WAVE1 · Tissues · Expression

Introduction

Epithelial ovarian cancer (EOC) is most common gynecological malignancy and is causes of cancer-related deaths in females worldwide [1–4]. Five-year survival for EOC is dependent on the clinical stage, and the most patients are also diagnosed at advanced stages where the prognosis of EOC patients is very poor [5, 6]. The tumorigenesis of EOC is associated with different reproductive, environmental, and genetic factors [7]. Therefore, diagnostic and prognostic biomarkers are required for the improving treatment strategies following primary debulking surgery.

Trypsin is belonged to serine protease family and encoded by PRSS1, PRSS2, and PRSS3 (trypsinogen I, trypsinogen II, and trypsinogen IV) [8]. Ectopic expression of PRSS3 was observed in some epithelial cancers and cancer cell lines that its expression has been reported to be linked to progression of cancer [9]. Previous studies indicated PRSS3 is involved in tumor progression, and others reported that trypsin or PRSS3 can be as tumor suppressive marker. It has been reported that PRSS3 expression level can be correlated with metastasis and

✉ Susan Azizmohammadi
dr.azizmohammadi@gmail.com

¹ Department of Gynecology, Hajar Hospital, AJA University of Medical Sciences, Tehran, Iran
² Department of Gynecology, Imam Reza Hospital, AJA University of Medical Sciences, Tehran, Iran
³ Department of Gynecology, Khanevadeh Hospital, AJA University of Medical Sciences, Tehran, Iran
⁴ Shahid Abbas Abdollahi, Molecular Biology Research Center, Shahid Mahallati Hospital, Tabriz, Iran
⁵ Department of Pharmaceutical Biotechnology, Faculty of Pharmacy, Lorestan University of Medical Sciences, Khorramabad, Iran
⁶ Department of Molecular Biology, Baqiyatallah University of Medical Sciences, Tehran, Iran

shorter survival in pancreatic and non-small cell lung cancers [10, 11]. In culture models, PRSS3 has been showed to promote cell proliferation and invasion in ovarian cancer, suggesting the important role of PRSS3 in metastasis [9]. Moreover, Wiskott–Aldrich syndrome protein family verprolin-homologous protein 1 (WAVE1) (member of WASP family) has been reported to be involved in cancer cell migration, metastasis, and invasion. In addition, decreased expression of WAVE1 has been reported to be correlated with reduction of invasion of prostate cancer cells and may act as effective target for cell metastasis prevention [12, 13].

Therefore, the present study was conducted to evaluate the clinical significance of PRSS3 and WAVE1 in EOC.

Materials and methods

Patients and tissue samples

In this study, a total of 39 paraffin-embedded tissue samples from EOC patients were surgically obtained between 2007 and 2013 in Tehran. Moreover, adjacent non-cancerous tissues from primary EOC patients were surgically obtained. All samples were snap-frozen in liquid nitrogen immediately after resection and were stored at -80°C . Written informed consent was obtained from all the participants. The clinical and pathological parameters are described in Tables 1 and 2. H&E slides were reviewed to evaluate the pathological features by two pathologists. Tumor stage was determined based on the International Federation of Gynecology and Obstetrics (FIGO).

Immunohistochemical analysis

Formalin-fixed paraffin embedded tissue was cut at 4- μm sections. The sections were dewaxed, rehydrated, and deparaffinized. Endogenous peroxidase activity was blocked by 3 % hydrogen peroxide for 10 min. Antigen retrieval was done in citrate buffer (pH 6.0) by the microwave oven method. After rinsing with PBS, nonspecific binding was blocked by using normal goat serum for 20 min at 37°C .

The slides were incubated with a primary antibody against PRSS3 (1:100) and goat anti-human WAVE1 (1:100) overnight at 4°C . The slides were incubated with a 1:30 dilution biotin-labeled secondary antibodies for 20 min at 37°C . Visualization was conducted using 3,3' diaminobenzidine tetrahydrochloride (Sigma) in PBS with 0.05 % H_2O_2 . Sections were lightly counterstained with hematoxylin. Staining intensity was graded as follow: Zero (0), weak staining (1+), moderate staining (2+), and strong staining (3+).

The staining score was defined as the staining intensity score multiplied by the percentage score (low expression between 0 and 4; high expression between 5 and 8).

Table 1 Correlation between PRSS3 expression and clinicopathological features of patients with epithelial ovarian cancer

Variable	Case no. 39	PRSS3 expression		<i>p</i> value
		Low=7	High=32	
Age				0.652
≤ 50	18	3	15	
> 50	21	4	17	
Grade				0.017
G1–G2	25	6	19	
G3	14	1	13	
FIGO stage				0.02
I–II	16	5	11	
III–IV	23	2	21	
Lymph node metastasis				0.001
Yes	26	2	24	
No	13	5	8	
Residual tumor (cm)				0.541
< 2	18	5	13	
≥ 2	21	2	19	
Histological subtypes				0.623
Serous	17	3	14	
Mucinous	10	1	9	
Endometrioid	5	2	3	
Clear cell	3	0	3	
Other	4	1	3	

Statistical analysis

All variables were analyzed by Software of SPSS version 16.0 (SPSS Inc, IL, USA). Differences between expression levels were evaluated using the Student's *t* test in cancer tissues and adjacent non-cancerous tissues. Association between expression levels and the clinicopathological characteristics was also evaluated using the chi-square test. Statistical analysis was considered to be statistically significant $P < 0.05$.

Results

PRSS3 expression

PRSS3 staining was observed in the cell membrane and cytoplasm of EOCs, and high PRSS3 immunoreactivity was detected in 32 patient's tissues (82.05 %), while seven cases (17.94 %) showed low expression (Fig. 1). Moreover, all adjacent non-cancerous tissues showed absent or low expression of PRSS3. As matter of fact, the expression of PRSS3 was significantly increased in the EOCs than adjacent non-cancerous tissues ($P < 0.00$).

Table 2 Correlation between WAVE1 expression and clinicopathological features of patients with epithelial ovarian cancer

Variable	Case no. 39	WAVE1 expression		<i>p</i> value
		Low=14	High=25	
Age				0.652
≤50	18	6	12	
>50	21	8	13	
Grade				0.011
G1–G2	25	10	15	
G3	14	4	10	
FIGO stage				0.001
I–II	16	9	7	
III–IV	23	5	18	
Lymph node metastasis				0.231
Yes	26	10	16	
No	13	4	9	
Residual tumor (cm)				0.041
<2	18	9	9	
≥2	21	5	16	
Histological subtypes				0.648
Serous	17	4	13	
Mucinous	10	5	5	
Endometrioid	5	2	3	
Clear cell	3	1	2	
Other	4	2	2	

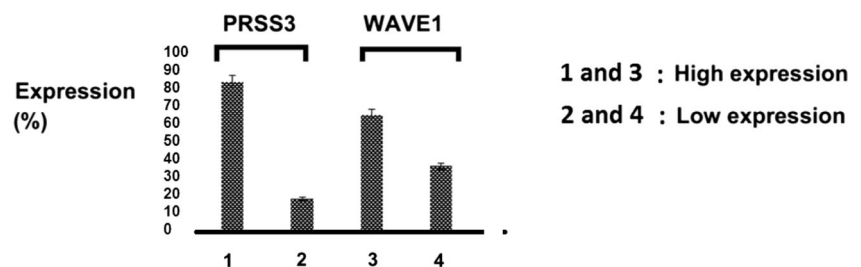
WAVE1 expression

Majority of EOC tissues showed both the cytoplasmic and the cytomembrane staining. High WAVE1 immunoreactivity was found in 25 patient's tissues (64.10 %), while 14 cases (35.89 %) showed low expression (Fig. 1). In fact, expression of WAVE1 was significantly observed in all EOC tissues when compared with normal tissues. Furthermore, WAVE1 expression was absent in 35 (89.74 %) adjacent non-cancerous tissues.

Correlation of expression of PRSS3 with clinicopathological features

Correlation of expression of PRSS3 with clinicopathological features was summarized in Table 1. Our findings showed that

Fig. 1 Expression level of PRSS3 and WAVE1 in patients with epithelial ovarian cancer



high expression of PRSS3 was significantly correlated with FIGO stage ($P=0.02$), advanced grade ($P=0.017$), and lymph node metastases ($P=0.001$), but no correlation was found with other clinicopathological features (Table 1).

Correlation of expression of WAVE1 with clinicopathological features

As showed in Table 2, high expression of WAVE1 was significantly correlated with FIGO stage ($P=0.001$), tumor grade ($P=0.011$), and residual tumor size ($P=0.041$), but there was not significant associations between WAVE1 expression and age, lymph node metastasis, and histological subtypes ($P>0.05$; Table 2).

Discussion

Previous studies indicated PRSS3 expression is involved in tumor progression [14]. In the present study, we evaluated the correlation between PRSS3 expression and clinical outcomes in patients with EOC by IH. Our finding indicated that all non-cancerous tissues had absent or low expression of PRSS3. The expression of PRSS3 was significantly increased in the EOCs than adjacent non-cancerous tissues. We also evaluated the correlation of expression of PRSS3 with clinicopathological features. Our findings showed that high expression of PRSS3 was significantly correlated with FIGO stage, advanced grade, and lymph node metastases. These findings preliminary indicated that increased expression of PRSS3 may be involved in development, progression, and metastasis of EOC. Of course, further investigations are needed to clarify the role of PRSS3 in EOC.

Previous studies have reported that expression of PRSS3 is related to the tumorigenesis in different kinds of cancers such as lung, colon, ovarian, pancreatic, and prostate cancers [9–11, 15]. It has been reported that PRSS3 expression level is correlated with metastasis and shorter survival in pancreatic and non-small cell lung cancers [10, 11]. It has been indicated that PRSS3 expression can promote cell proliferation and invasion in ovarian cancer tissues, indicating a potential role for PRSS3 in metastasis [9]. Overexpression of PRSS3 has been found in PC-3 cells, derived from a bone metastasis of a grade

4 prostatic adenocarcinoma [16]. Hockla et al. [17] indicated that PRSS3/mesotrypsin expression has an important functional role in promoting metastasis of prostate cancer. PRSS3 expression has been also reported to be involved in progression of pancreatic cancer, and its correlation with metastasis and poor survival has been found [11]. It has been demonstrated that PRSS3 expression increased metastasis and is linked to poor survival in lung cancer [10]. Furthermore, PRSS3 upregulation has been found to be involved in malignant growth in an in vitro model of breast cancer progression [18].

Yamashita et al. [19] indicated that expression of PRSS3 reduced in gastric adenocarcinoma and esophageal squamous cell carcinoma because of promoter hypermethylation-induced silencing.

This phenomenon (PRSS3 expression slanting) has been demonstrated in bladder and esophageal malignancies [20].

The conflicting result is likely associated with cell type- or tissue-specific functions of PRSS3. Further studies are required to clarify that how PRSS3 contributes to tumorigenesis.

Moreover, in our study, WAVE1 immunoreactivity was found in 25 patient's tissues (64.10 %), while 14 cases (35.89 %) showed low expression. In fact, the expression of WAVE1 was significantly observed in all EOC tissues when compared with normal tissues. Association of WAVE1 expression with clinicopathological features was evaluated in current study. Our results demonstrated that high expression of WAVE1 was markedly correlated with FIGO stage, tumor grade, and residual tumor size. These findings are consistent with other investigations of cancers [21, 22]. Previous studies have reported the correlation between overexpression of WAVE1 and cell migration or invasion in murine melanoma cell lines [23]. Overexpression of WAVE1 was also found to be involved in the invasion of prostate cancer cells and leukemia cells [13, 24]. Our finding showed that WAVE1 may be involved in development of EOC. Previous evidence demonstrated that the high expression of WAVE1 may play a key role in invasion and metastasis of ovarian cancer. In addition, overexpression of WAVEs has been showed to be associated with cell metastasis and poor prognosis in hepatocellular carcinoma and breast cancer [25, 26]. A previous study found that WAVE1 overexpression was significantly correlated with poor grade, advanced FIGO stage, residual tumor size, and serum Ca-125. They indicated that WAVE1 upregulation is related to an unfavorable prognosis and indicates that it can be as important predictor for EOC metastasis [27]. Further studies are required to evaluate the role WAVE1 and its involved mechanism in EOC.

In conclusion, our study showed that increased expression of PRSS3 and WAVE1 may be involved in development of EOC.

Compliance with ethical standards

Conflicts of interest None

References

- Jemal A, Siegel R, Xu J, Ward E. Cancer statistics, 2010. *CA Cancer J Clin.* 2010;60(5):277–300.
- Siegel R, Naishadham D, Jemal A. Cancer statistics, 2012. *CA Cancer J Clin.* 2012;62:10–29.
- Bast Jr RC, Hennessy B, Mills GB. The biology of ovarian cancer: new opportunities for translation. *Nat Rev Cancer.* 2009;9(6):415–28.
- Mirandola L, Cannon MJ, Cobos E, Bernardini G, Jenkins MR, Kast WM. Cancer testis antigens: novel biomarkers and targetable proteins for ovarian cancer. *Int Rev Immunol.* 2011;30:127–37.
- Cannistra SA. Cancer of the ovary. *N Engl J Med.* 2004;351:2519–29.
- Greenlee RT, Hill-Harmon MB, Murray T, Thun M. Cancer Statistics, 2001. *CA Cancer J Clin.* 2001;51:15–36.
- Romero I, Bast Jr RC. Minireview: human ovarian cancer: biology, current management, and paths to personalizing therapy. *Endocrinology.* 2012;153(4):1593–602.
- Paju A, Stenman UH. Biochemistry and clinical role of trypsinogens and pancreatic secretory trypsin inhibitor. *Crit Rev Clin Lab Sci.* 2006;43:103–42.
- Ma R, Ye X, Cheng H, Ma Y, Cui H, Chang X. PRSS3 expression is associated with tumor progression and poor prognosis in epithelial ovarian cancer. *Gynecol Oncol.* 2015;137(3):546–52.
- Diederichs S, Bulk E, Steffen B, Ji P, Tickenbrock L, Lang K. S100 family members and trypsinogens are predictors of distant metastasis and survival in early-stage non-small cell lung cancer. *Cancer Res.* 2004;64:5564–9.
- Jiang G, Cao F, Ren G, Gao D, Bhakta V, Zhang Y. PRSS3 promotes tumor growth and metastasis of human pancreatic cancer. *Gut.* 2010;59:1535–44.
- Takenawa T, Miki H. WASP and WAVE family proteins: key molecules for rapid rearrangement of cortical actin filaments and cell movement. *J Cell Sci.* 2001;114(10):1801–9.
- Fernando HS, Sanders AJ, Kynaston HG, Jiang WG. WAVE1 is associated with invasiveness and growth of prostate cancer cells. *J Urol.* 2008;180(4):1515–21.
- Radisky ES, Radisky DC. Matrix metalloproteinase-induced epithelial–mesenchymal transition in breast cancer. *J Mammary Gland Biol Neoplasia.* 2010;15:201–12.
- Akeuchi T, Shuman MA, Craik CS. Reverse biochemistry: use of macromolecular protease inhibitors to dissect complex biological processes and identify a membrane-type serine protease in epithelial cancer and normal tissue. *Proc Natl Acad Sci U S A.* 1999;96:11054–61.
- Dozmorov MG, Hurst RE, Culkin DJ, Kropp BP, Frank MB, Osban J. Unique patterns of molecular profiling between human prostate cancer LNCaP and PC-3 cells. *Prostate.* 2009;69:1077–90.
- Hockla A, Miller E, Salameh MA, Copland JA, Radisky DC, Radisky ES. PRSS3/mesotrypsin is a therapeutic target for metastatic prostate cancer. *Mol Cancer Res.* 2012;10(12):1555–66.
- Hockla A, Radisky DC, Radisky ES. Mesotrypsin promotes malignant growth of breast cancer cells through shedding of CD109. *Breast Cancer Res Treat.* 2010;124:27–38.

19. Yamashita K, Mimori K, Inoue H, Mori M, Sidransky D. A tumor-suppressive role for trypsin in human cancer progression. *Cancer Res.* 2003;63:6575–8.
20. Marsit CJ, Karagas MR, Danaee H, Liu M, Andrew A, Schned A. Carcinogen exposure and gene promoter hypermethylation in bladder cancer. *Carcinogenesis.* 2006;27:112–6.
21. Fernando HS, Davies SR, Chhabra A, Watkins G, Douglas-Jones A, Kynaston H. Expression of the WASP verprolin-homologues (WAVE members) in human breast cancer. *Oncology.* 2007;73(5–6):376–83.
22. Cai X, Xiao T, James SY, Da J, Lin D, Liu Y. Metastatic potential of lung squamous cell carcinoma associated with HSPC300 through its interaction with WAVE2. *Lung Cancer.* 2009;65(3):299–305.
23. Burns S, Cory GO, Vainchenker W, Thrasher AJ. Mechanisms of WASP-mediated haematological and immunological disease. *Blood.* 2004;104:3454–62.
24. He YL, Cao LZ, Yang MH, Zhao MY, Yu Y, Xu WQ. Role of WAVE1 in K562 leukemia cells invasion and its mechanism. *Zhonghua Xue Ye Xue Za Zhi.* 2009;30(4):237–41.
25. Iwaya K, Norio K, Mukai K. Coexpression of Arp2 and WAVE2 predicts poor outcome in invasive breast carcinoma. *Mod Pathol.* 2007;20(3):339–43.
26. Yang LY, Tao YM, Ou DP, Wang W, Chang ZG, Wu F. Increased expression of Wiskott–Aldrich syndrome protein family verprolin-homologous protein 2 correlated with poor prognosis of hepatocellular carcinoma. *Clin Cancer Res.* 2006;12(19):5673–9.
27. Zhang J, Tang L, Shen L, Zhou S, Duan Z, Xiao L, et al. High level of WAVE1 expression is associated with tumor aggressiveness and unfavorable prognosis of epithelial ovarian cancer. *Gynecol Oncol.* 2012;127(1):223–30.