

## Case Report

Middle East Journal of Cancer; July 2022; 13(3): 556-563

# Life-Saving Effect of Corticosteroid and Colchicine Combination in Acute Myeloid Leukemia: Case Report

Babak Abdolkarimi\*, MD, Mozghan Hashemieh\*\*†, MD, Arash Amin\*\*\*, MD

\*Department of Pediatrics Hematology/Oncology, Lorestan University of Medical Sciences, Khoramabad, Iran

\*\*Department of Pediatrics Hematology/Oncology, Shahid Beheshti University of Medical Sciences, Tehran, Iran

\*\*\*Department of Cardiology, Lorestan University of Medical Sciences, Khoramabad, Iran

## Abstract

In the present research, we reported an acute myeloid leukemia subject. The patient was treated with Cytarabine 200 mg/m<sup>2</sup> per day with continuous IV infusion on days 1, 2, 3, 4, Etoposide 100 mg/m<sup>2</sup> per day with continuous IV infusion on days 1, 2, 3, 4, Idarubicin 12 mg/m<sup>2</sup> as a 4-hour IV infusion on days 2, 4, 6, and Mitoxantrone 10 mg/m<sup>2</sup> as a 30-minute IV infusion on days 1, 2, 3. During treatment, the patient suffered from 3 life-threatening complications caused by chemotherapy drugs include sinusoidal obstruction syndrome (SOS), refractory thrombocytopenia, and pericardial effusion with pericardiocentesis limitation. To this end, we tried three novel approaches for patient management by Corticosteroid and Colchicine. Intravenous immunoglobulin infusion and oral prednisolone (2 mg/kg/d) were not effective in thrombocytopenia. However, eltrombopag (25 mg/kg/d) response was dramatic. Moreover, pericardial effusion and respiratory distress during the first chemotherapy course were managed with Lasix (2 mg/kg/d) and Spironolactone (25 mg/d); meanwhile, the massive pericardial effusion during the second chemotherapy course was managed with Colchicine (0.5 mg/d) through the mentioned treatment. Fortunately, these approaches were effective and life-saving.

**Keywords:** Leukemia, Myeloid, Acute, Hepatic veno-occlusive disease, Pericardial effusion

## Introduction

Acute myeloid leukemia (AML) is the second most prevalent disease in pediatric acute leukemia.<sup>1</sup> In the United States and Europe, the incidence has been stable with three to five cases per 100,000 individuals.

AML is treated via a highly potent chemotherapy regimen with severe complications. Its treatment complications could affect the main organs, including bone marrow, heart, liver, and kidney. The limitation of access to new drugs, in other words,

Please cite this article as: Abdolkarimi B, Hashemieh M, Amin A. Life-saving effect of corticosteroid and colchicine combination in acute myeloid leukemia: Case report. Middle East J Cancer. 2022;13(3):556-63-. doi: 10.30476/mejc.2022.87974.1449.

♦Corresponding Author:  
Mozghan Hashemieh, MD  
Department of Pediatrics  
Hematology/Oncology, Shahid  
Beheshti University of Medical  
Sciences, Tehran, Iran  
Email: mozghan.hashemieh@yahoo.com



their unavailability in low- or middle-income countries, is known to be a challenge for pediatric oncologists.<sup>2</sup>

Critical conditions, such as sinusoidal obstructive syndrome, steatosis, and pseudocirrhosis, are more commonly associated with chemotherapy. It is important to anticipate and recognize these adverse effects so that appropriate clinical measures could be taken. Patients with these liver manifestations can be normally managed with supportive therapies and Defibrotide. Liver toxicity may also be resolved after discontinuation of chemotherapy.<sup>3</sup> Defibrotide is unavailable in Iran.

Refractory thrombocytopenia limits many invasive procedures in oncologic patients, such as surgical operation or biopsy and other therapeutic or diagnostic actions. In this article, we solved three challenges of treatment employing new alternative treatment options.

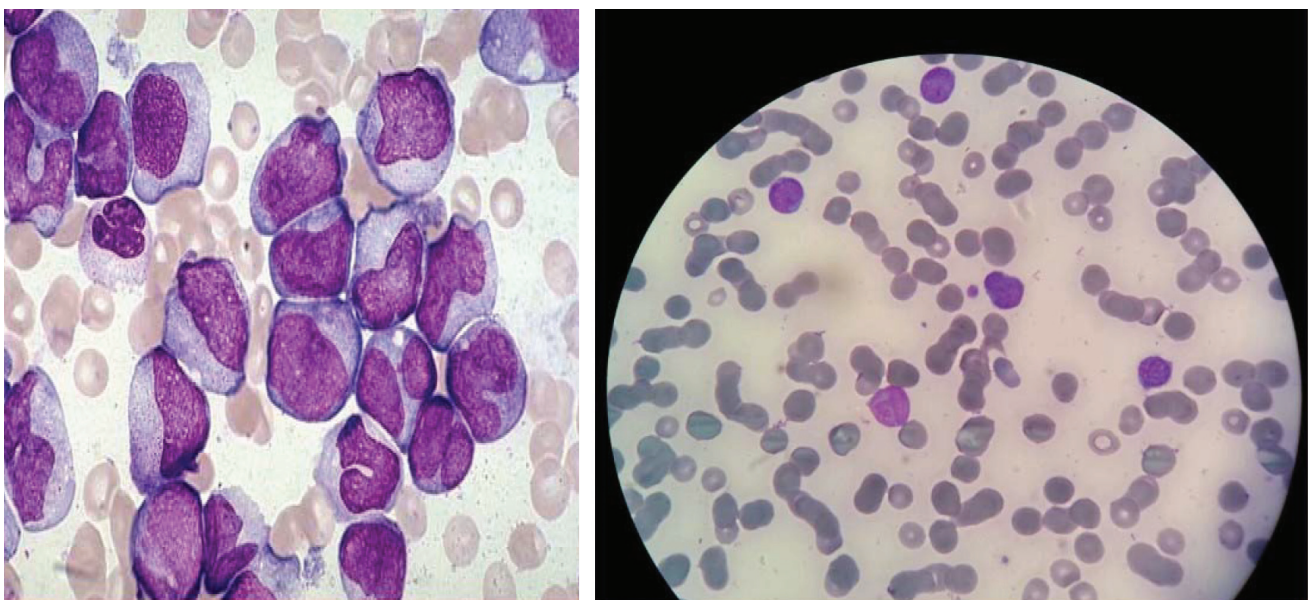
### Case Presentation

Our subject was a four year-old male patient from Iran presenting pancytopenia, who was admitted to Shahid Madani hospital (Khoramabad in Lorestan province/Iran). There was no history of any hematological disorders. On examination, the patient had pallor and mild splenic enlargement, measuring 1.5 cm on the left below

the costal margin.

Lymphadenopathy or any abnormal physical findings were unremarkable. The patient had been suffering from prolonged fever and nocturnal sweats along with weakness and fatigue. Morphology and immunophenotyping peripheral blood cells were examined with an automated hematologic analyzer (Sysmex, XE-5000, Vienna, Austria).

Peripheral blood smear examination showed normocytic normochromic red blood cells, including a few nucleated red blood cells. White blood cells showed shift to the left with a significant number of myeloid blast cells. Several giant platelets and platelet aggregates were seen. The leukocyte differential count was eosinophils 3%, lymphocytes 70%, and neutrophils 27%, and band forms 1%. Coagulation tests indicated a prolonged prothrombin time of 16.3 sec (reference range, 10.2 to 13.8), a normal activated partial Thromboplastin time, normal fibrinogen, and an increased D-dimer concentration of 4.96 mg/mL (reference range, 0 to 0.35). Bone marrow smears were stained with Wright-Giemsa and analyzed according to the routine clinical laboratory procedures. Bone marrow aspiration and biopsy showed an increased abnormal megakaryocytic. Monolobated and multinucleated megakaryocytic with hyperchromatic and pleomorphic nuclei were



**Figure 1.** Left side shows myeloblast in peripheral blood in Wright-Giemsa staining ( $\times 100$ ) and right side ( $\times 10$ ).

also seen, which showed that the myeloblast cells (Figure 1) were positive for CD13, CD33, CD34, CD14, CD71, CD117, MPO, HLA-DR, CD3, CD15, CD235a, and human leukocyte antigen-DR. The biochemical parameters, namely uric acid, bilirubin, creatinine, and liver enzymes, were normal. Serum LDH was highly increased. The diagnosis was confirmed as AML-M4.

Cytogenetic study of bone marrow myeloblasts showed t (8,21).

The patient was critically ill due to a high pulmonary pressure and respiratory distress. First echocardiography showed a high pulmonary pressure and a small amount of pericardial effusion. Lasix and Sildenafil were started for the patient.

Based on this diagnosis and concerning the patient's severely compromised overall condition, we started the therapy with Dutch-Belgian pediatric AML protocol for children with newly diagnosed AML:

First course: Ara-C Idarubicin Etoposide Thioguanin (AIET) induction

6-Thioguanin 100 mg/m<sup>2</sup> orally every 12 hours on days 1, 2, 3, 4.

Cytarabine 200 mg/m<sup>2</sup> per day with continuous IV infusion on days 1, 2, 3, 4;

Etoposide 100 mg/m<sup>2</sup> per day with continuous IV infusion on days 1, 2, 3, 4;

Idarubicin 12 mg/m<sup>2</sup> as a 4-hour IV infusion on days 2, 4, 6;

Triple intrathecal with Ara-C and MTX and Hydrocortisone was injected based on age-adjusted instruction. Age-adjusted dose; see table triple IT doses in the paragraph.

Second course: Ara-C Mitoxantrone (AM) induction

Cytarabine 100 mg/m<sup>2</sup> per day as continuous IV infusion on days 1, 2, 3, 4, 5;

Mitoxantrone 10 mg/m<sup>2</sup> as a 30-minute IV infusion on days 1, 2, 3;

Triple intrathecal injection similar to the first induction course. Age-adjusted dose; see table triple IT doses in the paragraph.

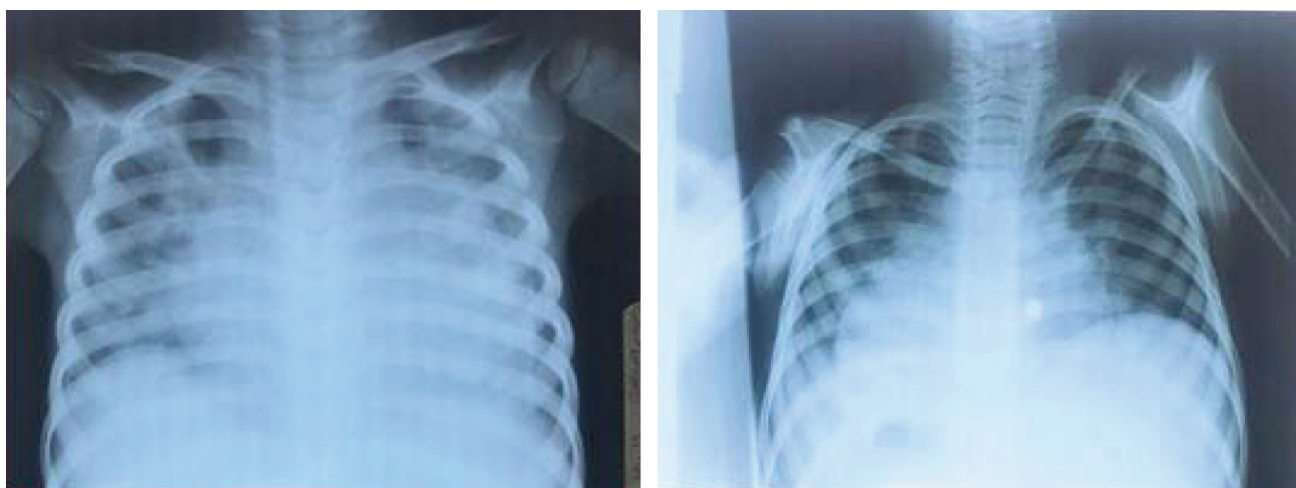
#### Consolidation therapy

Cytarabine 2 g/m<sup>2</sup> every 12 hours as a 2-hour IV infusion on days 1, 2, 3 (a total of six doses);

Etoposide 100 mg/m<sup>2</sup> as a 60-minute IV infusion on days 2, 3, 4, 5;

Triple intrathecal injection similar to the first and second induction courses. Age-adjusted dose; see table triple IT doses in the paragraph.

Following the first chemotherapy course, the patient was involved in refractory thrombocytopenia. Frequent infusion of the random donor or single donor apheresis platelets were done, but platelet count was sometimes greater than 20000. Intravenous immunoglobulin infusion and oral prednisolone (2 mg/kg/d) were not effective. After the second chemotherapy course, we treated him with eltrombopag (EP) (25 mg/kg/d). Furthermore, following the initiation of



**Figure 2.** Left side shows cardiomegaly due to pericardial effusion and right side shows decreasing effusion after prednisolone and Colchicine.



chemotherapy, in every course, the patient was involved in pericardial effusion. Pericardial effusion and respiratory distress during the first chemotherapy course were managed via Lasix (2 mg/kg/d) and Spironolactone (25 mg/d). Nevertheless, massive pericardial effusion during the second chemotherapy course was managed using Colchicine (0.5 mg/d) with the mentioned treatment (Figure 2).

After the third chemotherapy courses, the total and direct bilirubin increased, but transaminases were normal. Moderate Pitting edema and ascites were found in the patient. The liver looked large on examination. Serum albumin ranged from 2.5 to 3.5. Hepatic color Doppler sonography was normal. Sinusoidal obstruction syndrome or hepatic veno-occlusive disease (VOD) were suggested based on Baltimore criteria, but the liver biopsy was not done.

The morning after the initiation of HDMT (Day +13), serum AST, ALT, and total bilirubin were elevated to 459 U/L, 199 U/L, and 2.4 g/dL, respectively.

Prothrombin time was further prolonged (16.5 seconds; INR=1.56). BUN was 3 mg/dL and Cr 0.4 mg/dL. On the morning of Day +14, serum AST, ALT, total bilirubin, BUN, and Cr were 1108 U/L, 489 U/L, 2.9 g/dL, 5 mg/dL, and 0.5 mg/dL, respectively. By Day +15, serum AST, ALT, total bilirubin, and direct bilirubin had risen to 1494 U/L, 781 U/L, 3.4 g/dL, and 1.51 g/dL, respectively. Thereafter, the patient's condition improved gradually. One week later (Day +20), serum AST, ALT, and total bilirubin returned to 91 U/L, 197 U/L, and 1.4 g/dL, respectively. Blood and urine cultures were sterile.

Defibrotide is the standard treatment for hepatic VOD; however, this drug was not available in Iran.

We treated him with an alternative protocol as follows:

Methyl prednisolone pulse (30 mg/kg/d for three days) and UDCA (20 mg/kg/d)

The Ethics Committee of the Lorestan University of Medical Sciences approved the present case presentation (Ethics Code: IR.LUMS.REC.1400.304). Written informed consent was received from the patient.

## Discussion

Cytoreductive chemotherapy regimen in AML causes certain life-threatening complications, such as refractory thrombocytopenia, sinusoidal obstruction syndrome, and cardiovascular problems. Therefore, using the classic treatment of these challenges face limitations in the Iranian AML patients. Defibrotide is believed to be one of effective drugs for SOS, which is not available in Iran. Moreover, the use of eltrombopag in AML patients is accompanied with a high risk of disease progression.

Thrombocytopenia in AML is a life-threatening problem with a few treatment options. Platelet transfusions are limited by alloimmunization.

Frequent transfusion of ABO-mismatched platelets leads to early platelet refractoriness. ABO-mismatched platelets are as effective as matched platelets in patients with low-titer isoagglutinins, such as oncologic patients or those requiring only a few transfusions. However, the greater incidence of early refractoriness induced in major mismatched group (MMG) patients indicates that ABO-mismatched platelets should not be given to patients with marrow failure requiring a long-term support.<sup>4</sup> Concerning our patient, ABO-mismatched platelet was probably transfused due to the situation.

Furthermore, Rituximab, plasma exchange, and intravenous immunoglobulins (IVIg) are new treatment strategies for severe HLA alloimmune platelet refractoriness. These options can overcome severe platelet refractoriness owing to poly-specific HLA alloimmunization.<sup>5</sup> Our patient received IVIg without any response. We did not have any time for weekly Rituximab efficacy.

EP is an oral thrombopoietin receptor agonist, which increases platelet counts and has preclinical antileukemic activity.

In 2015, multi-center, randomized, placebo-controlled, trial patients aged 18 years or older, received EP doses up to 300 mg on a daily basis. There was an acceptable safety profile in patients with advanced myelodysplastic syndrome or acute myeloid leukemia.<sup>6</sup>

The treatment with EP results in a reduction in free intracellular iron in leukemic cells in a

dose-dependent manner. Increased intracellular iron eliminates the antiproliferative and induction effects of EP cell differentiation. Its antileukemic effects have been shown to be mediated by changes in the amount of intracellular iron.<sup>7</sup>

EP is also a safe and effective therapy for refractory thrombocytopenia after haplo-HSCT.<sup>8</sup> It could reduce platelet transfusion requirements in thrombocytopenic patients with advanced MDS and AML. EP might also be a treatment option for thrombocytopenic patients with AML or MDS, who are ineligible for other treatments and are not receiving disease-modifying treatment EP as escalated dose from 50 mg daily up to 200 mg daily up to 200 mg daily well-tolerated and has modest responses in heavily treated, predominantly higher-risk MDS patients or MDS/myeloproliferative neoplasm (MPN) or AML after HMA failure.<sup>9</sup>

Another use of EP in leukemia settings is in the treatment of severe refractory thrombocytopenia in chronic myelomonocytic leukemia (CMML),<sup>10</sup> and in immune thrombocytopenia (ITP) secondary to chronic lymphoproliferative disorder (CLL).<sup>11</sup>

Therefore, we did not worry about leukemia relapse during the drug use.

We treated our patient with dose 1 mg/kg/d because of the cost of drug. In addition, we utilized Prednisolone 1-2 mg/kg/d for a synergistic effect as a synergistic drug.

In 2016, a number of newly diagnosed AML patients aged >60 years (yrs) with ECOG scores of 0-2, no active second malignancy, and no evidence of marrow fibrosis at the time of AML diagnosis were treated with anthracycline (daunorubicin at 45 mg/m<sup>2</sup> or Idarubicin at 12 mg/m<sup>2</sup> x 3 days) and cytarabine (100 mg/m<sup>2</sup> x 7 days). Etlrombopag was administered and started from day 15. This study suggested that etlrombopag can accelerate platelet recovery, potentially reduce platelet transfusions, and increase complete remission rate (CR) in older AML patients.<sup>12</sup>

Regarding our patient, we did not detect any signs of relapse during etlrombopag administration.

Nonetheless, in 2019, Dr. Frey reported that etlrombopag in combination with induction of chemotherapy in patients with AML did not have favorable outcomes.<sup>13</sup> Despite this report, we should have used this drug herein since other treatments, such as platelet transfusion and IVIGs, were not efficacious.

Hepatic VOD, also called sinusoidal obstruction syndrome (SOS), rapidly progresses and involves life-threatening complications that can occur in patients receiving chemotherapy and/or bone marrow transplantation after heavy chemotherapy regimens. K<sup>+</sup>-sparing diuretic, low protein diet, and non-absorbable oral antibiotics are the general strategies for the management of this situation.

Hepatic VOD or sinusoidal obstruction syndrome is one of the adverse effects of chemotherapy drugs or severe combined chemotherapy regimens.

Chemotherapy-induced Sinusoidal Injury (CSI) score is a tool used as an immunohistochemical panel consisting of CD34, SMA, and GS. It may serve as an objective marker of chemotherapy-induced sinusoidal injury and could be conducive to diagnosis of this peculiar form of liver injury. Unfortunately, due to severe thrombocytopenia, pediatric gastrointestinal service rejects liver biopsy.

Platelet transfusions should be limited as much as possible because repeated platelet transfusion increases the risk of hepatic sinusoidal obstruction. This was not possible in our patient because there was a risk of life-threatening bleeding due to severe thrombocytopenia. Properly assessing fluid and electrolyte balance may be difficult due to the accumulation of ascites during SOS. In these cases, aggressive treatment with diuretics should be avoided due to the severe reduction in effective intravascular volume, which is prone to accumulation of sludge in the liver sinusoids.

Defibrotide is now the first-line therapy IV during the first 17-21 days.<sup>14</sup>

However, Defibrotide is not available in Iran and our patient had a life-threatening situation.

In 2008, Lun Chen and colleagues reported a case of rhabdomyosarcoma in a 21-month-old

boy who developed pancytopenia, dyspnea, jaundice, massive ascites, and body weight gain of more than 10% after receiving conventional chemotherapy. Hepatic VOD was diagnosed. He recovered after supportive care and treatment with high-dose methylprednisolone. He was diagnosed with VOD based on the above-mentioned findings, and Solumedrol was administered (15 mg/kg, every 12 hours for six doses).<sup>15</sup>

In addition, the third challenging problem in our patient was the combination of severe thrombocytopenia and massive pericardial effusion, which required pericardiocentesis, but due to severe thrombocytopenia, needle aspiration was not possible in this patient. Severe thrombocytopenia limited needle aspiration through the pericardium. Therefore, we had to treat our patient with medication. Moreover, there was counterindication concerning ASA and other NSAIDs in our case.

Colchicine is an anti-inflammatory agent used to treat gout and Behçet's disease. In gout, it is less preferred to NSAIDs or steroids. Some of its other uses include the prevention of pericarditis and familial Mediterranean fever.

Recent studies have reported that it is effective in the treatment of recurrent pericarditis. In our patient, we administered a combination of prednisone (2 mg/kg/d) and Colchicine (0.5 mg/d).

In 2013, Colchicine was used (at a dose of 0.5 mg) twice daily for 3 months for adult patients with acute pericarditis weighing >70 kg and 0.5 mg once a day for those weighing ≤70 kg. These patients treated with Colchicine added to conventional anti-inflammatory therapy, significantly reduced the rate of incessant or recurrent pericarditis.<sup>16</sup>

Experience with colchicine in the treatment of malignant pericardial effusion in solid tumors is relatively extensive, but experience with the use of this drug in the management of pericardial effusion due to leukemia is very limited. It is not a routine treatment.

Colchicine was administered as an adjunctive therapy after pericardiocentesis and not as a primary treatment.

In patients with malignant pericardial effusion who underwent pericardiocentesis, the use of Colchicine was associated with less all-cause mortality and reduced the need for subsequent interventions. In our patient, we only used drug therapy without pericardiocentesis.

Colchicine should be frequently administered in patients with adhesions and constriction after initial catheter drainage. Subsequently, the course of high-dose steroid should continue Colchicine for 4 months in order to prevent constriction.<sup>17</sup>

The concomitant occurrence of sinus obstruction syndrome (SOS) and refractory and severe thrombocytopenia, which requires repeated platelet transfusions, is a challenging and dangerous dilemma for the oncologist because repeated platelet transfusion cause platelets accumulation in the liver to repair sinusoidal cell damage, and these conditions creates critical and dangerous conditions for the patient while receiving myeloablative chemotherapeutic agents caused by SOS. This phenomenon also act as a platelet sequestration place.

Endothelial protective therapy or antiplatelet therapy, such as ASA, may be helpful in treating SOS. However, antiplatelet therapy had counterindication in our patient due to severe thrombocytopenia, but the treatment of endothelial inflammation of the liver sinusoids with a steroid pulse could facilitate the management of SOS in the absence of the drug of choice (defibrothyde) and save the patient's life.<sup>18</sup>

The interaction between Colchicine and platelet function was another challenge in this patient. Colchicine may have a beneficial cardiovascular effect by targeting the platelet-inflammatory axis. Whether targeting this pathway in vivo can offer protection from atherothrombosis without increasing the bleeding risk observed with traditional platelet-directed therapies remains unknown, for which future investigation is required.<sup>19</sup>

## Conclusion

In acute myeloid leukemia drugs, the side-effects are known to be a big challenge for oncologists. In developing countries, the use of

alternative therapies in the management of these complications instead of expensive and unattainable drugs is one of the most innovative treatment options for patients. The most important advantage of this solution is its cost-effectiveness and high efficacy. Steroids in various doses, along with Colchicine, have a life-saving role in improving the life-threatening side-effects of drugs in the liver (sinusoidal obstruction syndrome), heart (pericarditis), and bone marrow (transfusion-associated GVHD) of cancer patients.

### Acknowledgment

The authors would like to thank Dr. Amirpasha Tabaeian, associate professor of Gastroenterology, Iran University of Medical Sciences for their helpful comments.

### Conflict of Interest

None declared.

### References

- Hijjiya N, Ness KK, Ribeiro RC, Hudson MM. Acute leukemia as a secondary malignancy in children and adolescents: current findings and issues. *Cancer*. 2009; 115(1):23-35. doi: 10.1002/cncr.23988.
- Maksimovic N, Zaric M, Gazibara T, Trajkovic G, Maric G, Miljus D, et al. Incidence and mortality patterns of acute myeloid leukemia in Belgrade, Serbia (1999-2013). *Medicina (Kaunas)*. 2018;54(1):5. doi: 10.3390/medicina54010005.
- Masoumi-Dehshiri R, Hashemi A, Neamatzadeh H, Zare-Zardeini H. A case report: Acute myeloid leukemia (FAB M7). *Iran J Ped Hematol Oncol*. 2014;4(4):188-90.
- Carr R, Hutton JL, Jenkins JA, Lucas GF, Amphlett NW. Transfusion of ABO-mismatched platelets leads to early platelet refractoriness. *Br J Haematol* 1990;75(3):408-13. doi: 10.1111/j.1365-2141.1990.tb04356.x.
- Cid J, Magnano L, Acosta M, Alba C, Esteve J, Lozano M. Rituximab, plasma exchange and intravenous immunoglobulins as a new treatment strategy for severe HLA alloimmune platelet refractoriness. *Platelets*. 2015;26(2):190-4. doi: 10.3109/09537104.2014.895922.
- Afdhal NH, Giannini EG, Tayyab G, Mohsin A, Lee JW, Andriulli A, et al. Eltrombopag before procedures in patients with cirrhosis and thrombocytopenia. *N Engl J Med*. 2012;367(8):716-24. doi: 10.1056/NEJMoa1110709.
- Fu H, Zhang X, Han T, Mo X, Wang Y, Chen H, et al. Eltrombopag is an effective and safe therapy for refractory thrombocytopenia after haploidentical hematopoietic stem cell transplantation. *Bone Marrow Transplant*. 2019;54(8):1310-8. doi: 10.1038/s41409-019-0435-2.
- Mittelman M, Assouline S, Briasoulis E, Alonso A, Delgado RG, O'Gorman P, et al. Eltrombopag treatment of thrombocytopenia in advanced myelodysplastic syndromes and acute myeloid leukemia: Results of the 8-week open-label part of an ongoing study. *Blood*. 2012;120(21):3822. doi: 10.1182/blood.V120.21.3822.3822.
- Duong VH, Al Ali N, Zhang L, Padron E, Sallman D, Lancet JE, et al. A sequential two-stage dose escalation study of eltrombopag in patients with myelodysplastic syndrome and thrombocytopenia after hypomethylating agent failure. *Leuk Lymphoma*. 2020;61(8):1901-7. doi: 10.1080/10428194.2020.1751841.
- Gao Y, Gong M, Zhang C, Kong X, Ma Y. Successful eltrombopag treatment of severe refractory thrombocytopenia in chronic myelomonocytic leukemia: Two cases reports: A CARE-compliant article. *Medicine (Baltimore)*. 2017;96(43):e8337. doi: 10.1097/MD.0000000000008337.
- Visco C, Rodeghiero F, Romano A, Valeri F, Merli M, Quaresimini G, et al. Eltrombopag for immune thrombocytopenia secondary to chronic lymphoproliferative disorders: a phase 2 multicenter study. *Blood*. 2019;134(20):1708-11. doi: 10.1182/blood.201901617.
- Mukherjee S, Elson P, Bogati S, Woltman A, Desamito J, Gerds A, et al. A single-arm, phase II study of eltrombopag to enhance platelet count recovery in older patients with acute myeloid leukemia undergoing remission induction therapy. *Blood*. 2016;128(22):447. doi: 10.1182/blood.V128.22.447.447.
- Frey N, Jang JH, Szer J, Illés Á, Kim HJ, Ram R, et al. Eltrombopag treatment during induction chemotherapy for acute myeloid leukaemia: a randomised, double-blind, phase 2 study. *Lancet Haematol*. 2019;6(3):e122-e131. doi: 10.1016/S2352-3026(18)30231-X.
- Stevenson HL, Prats MM, Sasatomi E. Chemotherapy-induced Sinusoidal Injury (CSI) score: a novel histologic assessment of chemotherapy-related hepatic sinusoidal injury in patients with colorectal liver metastasis. *BMC Cancer*. 2017;17(1):35. doi: 10.1186/s12885-016-2998-2.
- Chen IL, Yang SN, Hsiao CC, Wu KS, Sheen JM. Treatment with high-dose methylprednisolone for hepatic veno-occlusive disease in a child with rhabdomyosarcoma. *Pediatr Neonatol*. 2008;49(4):141-4. doi: 10.1016/S1875-9572(08)60029-7.
- Imazio M, Belli R, Brucato A, Cemin R, Ferrua S, Beqaraj F, et al. Efficacy and safety of colchicine for



- treatment of multiple recurrences of pericarditis (CORP-2): a multicentre, double-blind, placebo-controlled, randomised trial. *Lancet*. 2014;383(9936):2232-7. doi: 10.1016/S0140-6736(13)62709-9.
17. Lutz A, Schelbert EB, Lontos K, Rossetti J, Katz W. Acute myeloid leukemia presenting as effusive constrictive pericarditis. *CASE (Phila)*. 2019;4(2):97-102. doi: 10.1016/j.case.2019.09.002.
  18. Nakanuma S, Miyashita T, Hayashi H, Tajima H, Takamura H, Tsukada T, et al. Extravasated platelet aggregation in liver zone 3 may correlate with the progression of sinusoidal obstruction syndrome following living donor liver transplantation: A case report. *Exp Ther Med*. 2015;9(4):1119-24. doi: 10.3892/etm.2015.2245.
  19. Shah B, Allen N, Harchandani B, Pillinger M, Katz S, Sedlis SP, et al. Effect of colchicine on platelet-platelet and platelet-leukocyte interactions: a pilot study in healthy subjects. *Inflammation*. 2016;39(1):182-9. doi: 10.1007/s10753-015-0237-7. Erratum in: *Inflammation*. 2016;39(1):501.