

Case Report

Follicular Dendritic Cell Sarcoma of the Thyroid Gland in a Patient with Preexisting Hashimoto's Thyroiditis: A Rare Case Report with a Literature Review

Seyed-ahmad Seyed-alagheband^a Mohammad-kazem Shahmoradi^a
Omid-Ali Adeli^b Tahereh Shamsi^c Maryam Schooli^d Ramin Shekouhi^d

^aDepartment of Surgery, Lorestan University of Medical Sciences, Khorramabad, Iran;

^bDepartment of Pathology, Lorestan University of Medical Sciences, Khorramabad, Iran;

^cStudent Research Committee, Shiraz University of Medical Sciences, Shiraz, Iran; ^dColorectal Research Center, Department of Surgery, Shiraz University of Medical Sciences, Shiraz, Iran

Keywords

Dendritic cell sarcoma · Follicular dendritic cells · Thyroidectomy · Immunohistochemistry · Hashimoto disease

Abstract

Thyroid follicular dendritic cell sarcoma (FDSC) is an extremely rare malignancy that originates from follicular dendritic cells of the thyroid germinal centers. To the best of our knowledge, there are only 4 reported cases of thyroid FDSC in the English literature. Herein, we present the fifth case of FDSC of the thyroid gland. A 63-year-old woman presented with a painless midline neck mass, enlarging for the last 4 months. Physical examination revealed a 6-cm nonmobile, firm, multinodular thyroid mass with palpable cervical lymphadenopathy. Due to high suspicion for thyroid malignancy, the patient underwent total thyroidectomy with bilateral modified radical neck dissection. Histologic evaluations revealed sheets of storiform eosinophilic tumoral cells with prominent nucleoli containing multinucleated giant cells, and subsequent immunohistochemistry showed immunoreactivity for CD4, CD21, CD35, CD45 (LCA), and CD68. The patient was started on 6 cycles of doxorubicin, ifosfamide, and radiotherapy. She has had monthly thyroid ultrasonography and contrast-enhanced thoracoabdominal CT scan every 3 months for detecting potential recurrence and/or metastasis screening. Fortunately, 8 months after the operation, the patient is alive without any signs of local or distant metastasis.

© 2021 The Author(s).
Published by S. Karger AG, Basel

Correspondence to:
Ramin Shekouhi, shekouhi.ramin@gmail.com

Introduction

Follicular dendritic cell sarcoma (FDSC) is a rare low-grade malignancy first described by Monda et al. [1]. It originates from the antigen-presenting dendritic cells and most commonly presents as a slow-growing painless mass within cervical lymph nodes. However, FDSC can be detected at other lymphoid structures and even extranodal sites [2]. While usual extranodal sites of involvement include the tonsils, nasopharynx, peritoneum, and pancreas [3], the thyroid is considered an extremely rare location for primary FDSC to occur. To the best of our knowledge, there are only 4 reported cases of thyroid FDSC in the English literature [4]. Herein, we present the fifth case, a 63-year-old woman presented with a painless neck lump which showed immunohistochemical characteristics of FDSC, after examining specimen total thyroidectomy with bilateral modified radical neck dissection.

Case Presentation

A 63-year-old woman presented with a painless neck mass that had been growing for the last 4 months prior to the first visit. The patient did not complain of dysphagia, dyspnea, hoarseness, or weight loss. The past medical history was significant for Hashimoto thyroiditis, for which she was being treated with levothyroxine. Also, family history revealed Hashimoto thyroiditis in her mother and second cousin. A firm, nontender, multinodular, fixed midline thyroid mass measuring 60 mm × 35 mm in diameter with palpable bilateral cervical lymphadenopathy in cervical zones of II–VI was noted in physical examination. The lymph nodes were firm, fixed, and nonmobile. Laboratory studies, including thyroid function tests, serum metanephrine, calcitonin, calcium, PTH, and CEA, were all within normal ranges and unremarkable.

Thyroid ultrasonography revealed a heterogeneous hypoechoic multinodular mass measuring 70 mm × 50 mm × 32 mm with multiple reactive lymph nodes in bilateral jugular chains, the largest of them measuring 20 mm × 11 mm × 6 mm. Also, bilateral supraclavicular lymph node enlargement was noted during the ultrasonography. Computed tomography (CT) scan with intravenous (IV) contrast revealed multiple heterogeneous thyroid nodules with possible internal necrosis. Accordingly, there were no signs of tumor invasion to the trachea, larynx, esophagus, carotid arteries, jugular veins, and cervical spines (Fig. 1).

Fine needle aspiration (FNA) cytology of the mass revealed hypercellular smears containing scattered isolated atypical cells and rare multinucleated cells in a bloody field, which was in favor of anaplastic or medullary carcinoma of the thyroid. However, FNA cytology of the left cervical lymph nodes was in favor of metastatic carcinoma, which led us to investigate for an underlying malignancy. Upper and lower gastrointestinal endoscopy was unremarkable. Also, the patient underwent contrast-enhanced thoracoabdominal and brain CT scan which showed no signs of metastasis.

Treatment

Due to high suspicion for thyroid malignancy, the patient was scheduled for surgery. Total thyroidectomy with bilateral modified radical neck dissection was conducted under general anesthesia with the purpose of complete resection of the tumor and involved lymph nodes (Fig. 2). Accordingly, there were no signs of invasion to the trachea, esophagus, carotid arteries, paravertebral fascia, and cervical spines. Gross examination revealed a relatively well-circumscribed tan-colored mass with a creamy rubbery cut surface. Microscopic examination

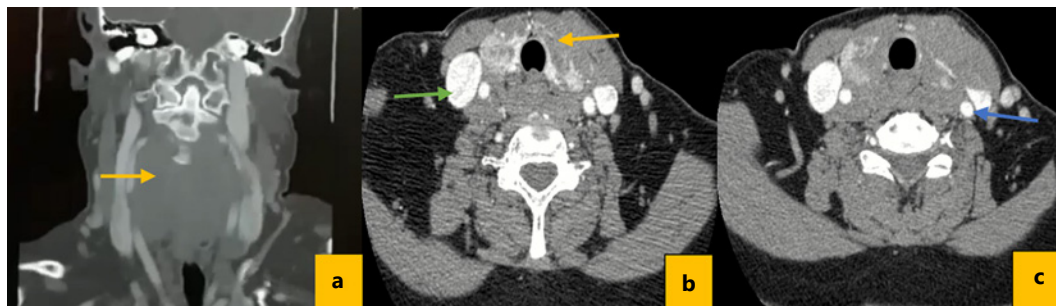


Fig. 1. Cervical CT scan with IV contrast. **a** Multiple heterogeneous thyroid nodules with possible internal necrosis (yellow arrow). **b, c** Green and blue arrows outline the internal jugular vein and carotid artery, respectively.

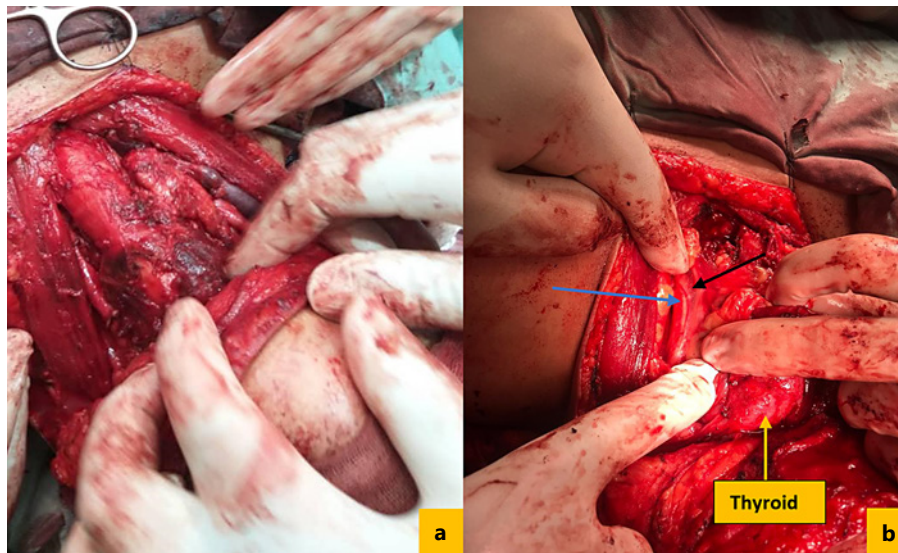


Fig. 2. **a** Total thyroidectomy with bilateral MRND. Blue and black arrows in **(b)** outline carotid sheet and vagus nerve, respectively. MRND, modified radical neck dissection.

revealed sheets of storiform eosinophilic tumoral cells with prominent nucleoli containing multinucleated giant cells. Most tumor cells showed discohesive features of focal anaplastic appearance. No epithelial structure was observed. Involved lymph nodes showed infiltration with large eosinophilic cells resembling the thyroid mass. Subsequent immunohistochemistry showed immunoreactivity for CD4, CD21, CD35, CD43, CD45 (LCA), CD68, and CD123 with high Ki-67 index. However, tumor cells were negative for CD3, CD5, CD10, CD20, MPO, and PAX5 (Fig. 3).

Outcome and Follow-Up

Two days following the surgery, the patient developed symptomatic hypocalcemia. After a consult with endocrinology service, she received a single IV dose of calcium gluconate with calcium and vitamin D supplementations. The patient was discharged 10 days after the operation with permanent calcium adjustments. After discharge, she received 6 cycles of

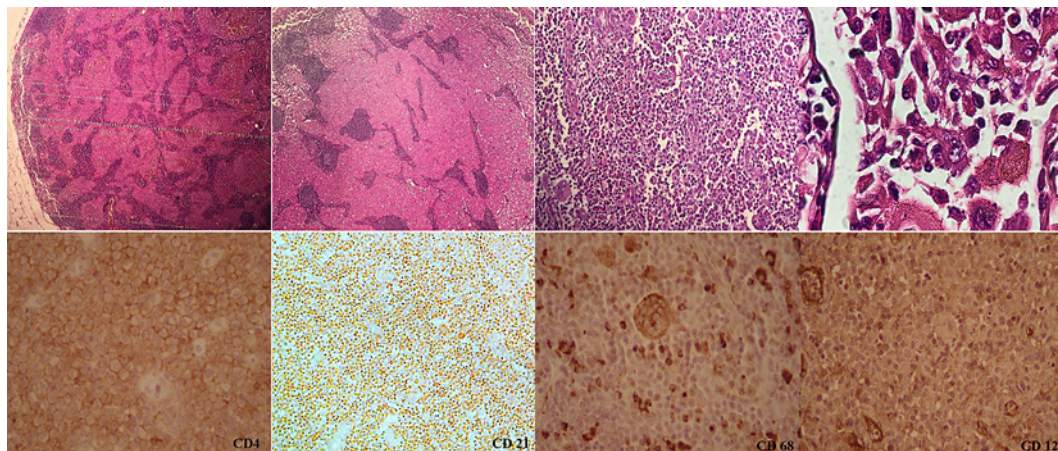


Fig. 3. Microscopic examination revealed sheets of storiform eosinophilic tumoral cells with prominent nucleoli containing multinucleated giant cells. Immunohistochemistry showed immunoreactivity for CD4, CD21, CD45 (LCA), CD35, CD68, CD43, and CD123 with high Ki-67 index.

chemotherapy with doxorubicin and ifosfamide in conjunction with radiotherapy. She has had monthly thyroid ultrasonography and contrast-enhanced thoracoabdominal CT scan every 3 months for recurrence and early metastasis screening. Fortunately, 8 months after the operation, the patient is alive without any signs of local or distant metastasis.

Discussion

FDSC, a reticuloendothelial system neoplasm, primarily originates in the lymph nodes, but extranodal occurrences can happen too. Extranodal FDSC is often misdiagnosed with other malignancies including thymoma, SCC, and neoplasias involving the reticuloendothelial system and may therefore go undiagnosed [2]. Positivity for Epstein-Barr virus in situ hybridization and Castleman's disease are considered as known risk factors for FDSC. Castleman's disease is a lymphoproliferative disorder, frequently characterized as giant lymph node hyperplasia [5, 6]. However, these FDSC-related risk factors were not found in most of the reported thyroid FDSC cases [7]. Thyroid FDSC usually manifests in patients with preexisting Hashimoto's thyroiditis, as all the previous cases had Hashimoto's thyroiditis except one of them [5, 8–10]. In this study, the patient was also a previous case of longstanding Hashimoto's thyroiditis.

Thyroid FDSC primarily involves patients 36–65 years old, and the average diagnosis age for FDSC is 50 years [11]. While FDSC is showing a gender neutral prevalence with a 1:1 male to female ratio, primary thyroid involvement is more common among women (85.7%) [12]. Overall, the most common presenting symptoms of FDSC is lymphadenopathy (64%) followed by dyspnea, dysphagia, weight loss, and fatigue [5]. Patients with thyroid FDSC, on the other hand, usually complain of a slowly growing neck mass, without any systemic symptoms. Surprisingly, the majority of thyroid FDSC patients were euthyroid.

Diagnosis of thyroid FDSC is extremely challenging due to nonspecific clinical symptoms and extreme rarity. Imaging studies including ultrasound and cervical CT scan usually fall short in differentiation of thyroid FDSC from other thyroid malignancies. Nevertheless, radiologic evaluations are mainly used to assess tumor size, location, and local invasion to surrounding structures. On ultrasound, thyroid FDSC may appear as an isoechoic or hypoechoic

mass with cervical lymph node involvement [10]. If ultrasonography was equivocal, the next step in diagnosis would be CT scan, which provides useful information regarding tumor texture and lymph node involvement. Furthermore, ultrasonography-guided fine needle aspiration cytology is a more definite method to diagnose thyroid FDCS [10].

Histologically, the thyroid FDCS is primarily a spindle cell tumor composed of spindle- or oval-shaped cells demonstrating a storiform or whorled growth model, organized in sheets, nets, and focal fascicles [13]. In some cases, epithelioid cells and multinucleated giant cells may also be found [14]. Immunohistochemistry is an essential indicator for accurate diagnosis of thyroid FDCS. These tumors are typically positive for dendritic cell markers including CD21, CD23, CD35, CD45, and clusterin (Table 1). Also, the tumors variably show positive S-100, CD68, vimentin, and specific muscle actin. Tumor markers, CD21 and CD35, have higher sensitivity and specificity, which help us in distinguishing thyroid FDCS from other types of sarcomas [14, 15].

Complete surgical resection with tumor-free margins is considered the best treatment option for thyroid FDCS. Accordingly, all previous cases of thyroid FDCS underwent thyroidectomy and neck dissection. However, due to disease rarity, there is not enough evidence on the optimal therapeutic option. The advantages of adjuvant chemotherapy and radiotherapy remain to be controversial. Radiation therapy is generally recommended for extracapsular involvement, high mitosis activity, and abundant nuclear pleomorphism with residual disease [8, 10]. Absence of lymphoplasmacytic response, tumor size >6 cm, cellular atypia, or high mitotic index (≥ 5 per 10 HPF) are considered poor prognostic factors for thyroid FDCS [13, 16, 17]. Medications such as cyclophosphamide, doxorubicin, vincristine, and prednisone (i.e., lymphoma-based treatment) are among the most commonly used regimens in the treatment of this neoplasm. There is also some experience with sarcoma-based regimens including gemcitabine, ifosfamide, and etoposide [18, 19]. All in all, the prognosis for thyroid FDCS seems favorable, similar to its nodal or extranodal counterparts [5].

Conclusion

Thyroid FDCS is a neoplasm that can be missed easily due to its extreme rarity. In the current study, we reported a 63-year-old woman with controlled Hashimoto's thyroiditis who developed a midline neck mass. After carrying out a plethora of tests and imaging studies, the pathology report pointed out thyroid FDCS as the diagnosis. While thyroid FDCS, owing to its extreme rarity, is harder to diagnose than other types of head and neck FDCS, its treatment and prognosis does not differ vastly from other types of head and neck FDCS. Hashimoto thyroiditis seems to be the most important risk factor for thyroid FDCS as all of the cases in the English literature, including our case, have had this illness prior to occurrence of the neoplasm.

Statement of Ethics

The present study was approved by the Medical Ethics Committee of the Lorestan University of Medical Sciences, and the approval was issued on March 21, 2021. The purpose of this research was completely explained to the patient and was assured that the information will be kept confidential by the researchers. Written informed consent was obtained from the patient for publication of this case report and any accompanying images. A copy of the written consent is available for review by the editor-in-chief of this journal.

Table 1. All previous cases of FDSC of the thyroid gland ever published in the English literature

Case	Age/ sex	Symptoms	Histology	Immunohistochemistry	Local/distant metastasis	Treatment
Galati et al. [5]	65/F	A slowly growing mass	Spindle-shaped tumoral cells with large nuclei and prominent nucleoli	CD-21 and vimentin	No	Total thyroidectomy, right modified radical neck dissection, radiotherapy
Yu and Yang [20]	58/F	Painless cervical mass	Spindle cell proliferation in fascicles with eosinophilic cytoplasm resulting in a syncytial appearance	Positive for CD68 (KP1), CD35, and fascin. CD21 and CD23 were negative	n/a	Subtotal thyroidectomy
Starr et al. [10]	44/F	A palpable right-sided thyroid nodule	Spindle in storiform patterns with occasional multinucleated giant cells	Positive for CD21, CD23, vimentin, clusterin, fascin	n/a	Total thyroidectomy, central compartment dissection, radiotherapy
Zhang et al. [4]	48/F	A slow-growing mass in the left thyroid	Spindle cells with fascicle, and concentric whorl patterns	Positive for CD21, CD35, CD23, vimentin, CD68, S100 (partial, CD5, and TdT)	No	Total thyroidectomy and left modified radical neck dissection
Our case	63/F	Painless neck mass	Sheets of storiform eosinophilic tumoral cells with prominent nucleoli	Positive for CD4, CD21, CD45 (LCA), CD35, CD68, CD43	No	Total thyroidectomy with bilateral modified radical neck dissection

Conflict of Interest Statement

The authors declare that they have no competing interests.

Funding Sources

No funding was obtained for this study.

Author Contributions

S.S. and M.S. drafted the manuscript and provided surgical images. O.-A.A. and T.S. helped with the draft and provided histologic evaluations. M.S. reviewed the literature, and R.S. (corresponding author) supervised, provided initial feedback, and reviewed the final manuscript. The authors read and approved the final manuscript.

Data Availability Statement

All data generated or analyzed during this study are included in this published article.

References

- 1 Monda L, Warnke R, Rosai J. A primary lymph node malignancy with features suggestive of dendritic reticulum cell differentiation. A report of 4 cases. *Am J Pathol*. 1986;122(3):562.
- 2 Chen T, Gopal P. Follicular dendritic cell sarcoma. *Arch Pathol Lab Med*. 2017;141(4):596–9.
- 3 Biddle DA, Ro JY, Yoon GS, Yong YW, Ayala AG, Ordonez NG, et al. Extranodal follicular dendritic cell sarcoma of the head and neck region: three new cases, with a review of the literature. *Mod Pathol*. 2002; 15(1):50–8.
- 4 Zhang T, He L, Wang Z, Dong W, Sun W, Zhang P, et al. Follicular dendritic cell sarcoma presenting as a thyroid mass: an unusual case report and literature review. *J Int Med Res*. 2020;48(6):300060520920433.
- 5 Galati LT, Barnes EL, Myers EN. Dendritic cell sarcoma of the thyroid. *Head Neck*. 1999;21(3):273–5.
- 6 Farah CS, Zaini ZM, Savage NW, Norris D. Follicular dendritic cell sarcoma associated with Castleman's disease presenting in the oral cavity. *Oral Oncol Extra*. 2006;42(3):94–7.
- 7 Chan AC, Chan KW, Chan JK, Au WY, Ho WK, Ng WM. Development of follicular dendritic cell sarcoma in hyaline-vascular Castleman's disease of the nasopharynx: tracing its evolution by sequential biopsies. *Histo-pathology*. 2001;38(6):510–8.
- 8 Zhang T, He L, Wang Z, Dong W, Sun W, Zhang P, et al. Follicular dendritic cell sarcoma presenting as a thyroid mass: an unusual case report and literature review. *J Int Med Res*. 2020;48(6):300060520920433.
- 9 Yu L, Yang SJ. Primary follicular dendritic cell sarcoma of the thyroid gland coexisting with Hashimoto's thyroiditis. *Int J Surg Pathol*. 2011;19(4):502–5.
- 10 Starr JS, Attia S, Joseph RW, Menke D, Casler J, Smallridge RC. Follicular dendritic cell sarcoma presenting as a thyroid mass. *J Clin Oncol*. 2015;33(17):e74–6.
- 11 Parada D, Peña KB, Riu F, Saperas LAC. Follicular dendritic cell sarcoma and invasive carcinoma of the breast. *Hum Pathol*. 2017;9:38–42.
- 12 Li X-Q, Cheuk W, Lam PW, Wang Z, Loong F, Yeong M-L, et al. Inflammatory pseudotumor-like follicular dendritic cell tumor of liver and spleen: granulomatous and eosinophil-rich variants mimicking inflammatory or infective lesions. *Am J Surg Pathol*. 2014;38(5):646–53.
- 13 Chan JK, Fletcher CD, Nayler SJ, Cooper K. Follicular dendritic cell sarcoma. Clinicopathologic analysis of 17 cases suggesting a malignant potential higher than currently recognized. *Cancer*. 1997;79(2):294–313.
- 14 Idrees MT, Brandwein-Gensler M, Strauchen JA, Gil J, Wang BY. Extranodal follicular dendritic cell tumor of the tonsil: report of a diagnostic pitfall and literature review. *Arch Otolaryngol Head Neck Surg*. 2004;130(9): 1109–13.
- 15 Clement P, Saint-Blancard P, Minvielle F, Le Page P, Kossowski M. Follicular dendritic cell sarcoma of the tonsil: a case report. *Am J Otolaryngol*. 2006;27(3):207–10.

- 16 Agaimy A, Michal M, Hadravsky L, Michal M. Follicular dendritic cell sarcoma: clinicopathologic study of 15 cases with emphasis on novel expression of MDM2, somatostatin receptor 2A, and PD-L1. *Ann Diagn Pathol*. 2016;23:21–8.
- 17 Kara T, Serinsoz E, Arpaci RB, Vayisoglu Y. Follicular dendritic cell sarcoma of the tonsil. *BMJ Case Rep*. 2013; 2013:bcr2012007440.
- 18 Soriano AO, Thompson MA, Admirand JH, Fayad LE, Rodriguez AM, Romaguera JE, et al. Follicular dendritic cell sarcoma: a report of 14 cases and a review of the literature. *Am J Hematol*. 2007;82(8):725–8.
- 19 Fonseca R, Yamakawa M, Nakamura S, van Heerde P, Miettinen M, Shek TW, et al. Follicular dendritic cell sarcoma and interdigitating reticulum cell sarcoma: a review. *Am J Hematol*. 1998;59(2):161–7.
- 20 Yu L, Yang SJ. Primary follicular dendritic cell sarcoma of the thyroid gland coexisting with hashimoto's thyroiditis. *Int J Surg Pathol*. 2009.