

# Effect of royal jelly on testicular antioxidant enzymes activity, MDA level and spermatogenesis in rat experimental Varicocele model

Nematollah Asadi<sup>a,b</sup>, Arash Kheradmand<sup>c,\*</sup>, Mohammadreza Gholami<sup>d</sup>, Seyed Hojatollah Saidi<sup>e</sup>, Seyed Ahmad Mirhadi<sup>b</sup>

<sup>a</sup> Razi Herbal Medicines Research Center, Lorestan University of Medical Sciences, Khorramabad, Iran

<sup>b</sup> Animal Sciences Research Institute (ASRI) of Jihad-e-Agriculture Ministry, Iran

<sup>c</sup> Department of Clinical Sciences, School of Veterinary Medicine, Lorestan University, Lorestan University, P.O.Box: 465, Khorram Abad, Iran

<sup>d</sup> Kermanshah University of Medical Sciences, Kermanshah, Iran

<sup>e</sup> Omid Fertility Clinic, Tehran, Iran

## ARTICLE INFO

### Keywords:

Royal jelly

Varicocele

Antioxidant enzymes

## ABSTRACT

Varicocele is one of the most prevalent causes of infertility. It causes induction of oxidative stress, increases lipid peroxidation in the testis and disrupts spermatogenesis cycle. The aim of the study was to investigate the possible protective effects of royal jelly against varicocele induced oxidative stress, biochemical and histological alterations in the experimental varicocele model in rat. Twenty-one adult Wistar rats were divided into three groups. The control group (I), Varicocele and administration of normal saline (II), varicocele and treatment with RJ (III). At the end of the experiment, all the animals were sacrificed and testes excised. The activity of catalase (CAT), superoxide dismutase (SOD), glutathione peroxidase (GPx) and MDA levels were measured. Also, histopathological examinations, Johnsen scores and sperm parameters were determined. There was a significant ( $p < 0.05$ ) increase in the activity level of CAT ( $0.223 \pm 0.005$ ), SOD ( $0.177 \pm 0.0062$ ), GPx ( $9.575 \pm 0.318$ ) and a significant ( $p < 0.05$ ) reduction in the MDA level ( $2.674 \pm 0.336$ ) of the experimental varicocele treated with royal jelly when compared to the activity of CAT ( $0.011 \pm 0.004$ ), SOD ( $0.035 \pm 0.0096$ ), GPx ( $8.864 \pm 0.397$ ) and MDA level ( $4.630 \pm 0.579$ ) of the experimental varicocele and administration of normal saline. Results of the Johnsen score showed a significant increase ( $p < 0.05$ ) in the mean score of the RJ group ( $7.94 \pm 1.5$ ) when compared to the normal saline group ( $6.04 \pm 1.4$ ). Therefore, RJ is a potential area for further studies and improving in spermatogenesis cycle after varicocele.

## 1. Introduction

Varicocele remains the most common cause of male infertility worldwide. This complication found in 15% of all men and in 19%–41% of men who present with primary infertility, representing the most common surgically treatable cause of male infertility. In men with secondary infertility, varicoceles are an underlying cause in 45%–81% of patients (Pastuszak and Wang, 2015). Ten studies in meta-analysis involving 1232 men show that varicocele is associated with a reduction in sperm count, motility and morphology (Agarwal et al., 2016). Studies have shown that varicocele occurrence is associated with excessive production of reactive oxygen species (ROS). Superoxide anion radical, hydrogen peroxide, oxygen singlet and proxy nitrite radical are highly reactive species (Khatri and Juvekar, 2013). They can cause pathological damage by inducing oxidative changes in cellular lipids, proteins,

and implicate sperm dysfunction (Smith et al., 2006; Bromfield et al., 2015; Di Meo et al., 2016). Therefore, the ROS level is an important parameter for assessing the treatment of varicocele-induced infertility. Although varicolectomy can improve semen parameter (for example, sperm count, motility or morphology) and there is high-level evidence to suggest that in the varicocele patients, varicolectomy results in improvement of outcomes. But the role of varicocele repair for the treatment of subfertile men has been questioned during the past decades (Agarwal et al., 2012; Cho and Seo, 2014). Some studies have shown that there is no beneficial effect of varicocele repair on a couple's chance of conception (Evers and Collins, 2004; Evers et al., 2008). Therefore, Varicocele repair is not necessarily recommended for all infertile men with varicocele, and currently existing guidelines suggest some considerations for selecting candidates for surgical or radiological treatments. Reports have shown that Varicocele repair presents

\* Corresponding author.

E-mail address: [arashkheradmand@yahoo.com](mailto:arashkheradmand@yahoo.com) (A. Kheradmand).

<https://doi.org/10.1016/j.tice.2019.02.005>

Received 8 September 2018; Received in revised form 18 February 2019; Accepted 19 February 2019

Available online 20 February 2019

0040-8166/ © 2019 Elsevier Ltd. All rights reserved.

relatively few risks, which might include, buildup of fluid around the testicles (hydrocele), recurrence of varicocele, infection and damage to an artery. Therefore, considering the prevalence of varicocele in adolescents and surgical injury caused to correct the condition, the antioxidant treatments are necessary to counteract their harmful effects (Agarwal et al., 2005). The antioxidant compounds react in one-electron reactions with free radicals *in vivo/in vitro* and prevent oxidative damage. Therefore, the natural antioxidants not only play an important role in the prevention and adjunctive treatment of diseases but also can avoid the adverse reactions to human health. For example, study of 219 men with varicocele also reported an increase in sperm concentration and motility and improved morphology after 4 months using L-carnitine and acetyl-L-carnitine (Balercia et al., 2005). Oliva et al. examined the effect of 12 weeks of daily oral administration of pentoxifylline with zinc and folic acid on the semen quality of 36 men with varicocele-associated infertility in an open, uncontrolled study. After 4 weeks of treatment, the proportion of morphologically normal sperm cells was significantly increased; these changes persisted until at least 4 weeks after the end of treatment (Oliva et al., 2009). Wong et al. observed an increased sperm count and improved semen concentration in a controlled trial with 103 infertile and 107 fertile men who had taken 5 mg folic acid and 66 mg ZnSO<sub>4</sub> per day for 6 months (Wong et al., 2002). Royal jelly is a natural substance that is considered to be one of the most important products of honeybees (Barnutiu et al., 2011). It is secreted from the glands in the hypopharynx of worker bees. All larvae in the colony are fed with RJ regardless of sex or caste (Barnutiu et al., 2011). The chemical composition analysis shows that this natural substance contains a complex mixture of free amino acids, proteins, sugars, fatty acids (mainly 10-hydroxy-2-decenoic acid), minerals (mainly iron and calcium), vitamins (mainly thiamine, niacin, riboflavin, and vitamins A, C, D and E), nucleic acids, acetylcholine, aspartic acid, and gelatin, sterols (Cavusoglu et al., 2009). Studies show the antioxidant property of RJ (Nekeety et al., 2007; Nakajima et al., 2009; Silici et al., 2011; Ghanbari et al., 2015), especially when the RJ is used 24 h after the larvae transfer (Mahbobi et al., 2012). More than 12 antioxidant peptides in RJ have been identified showed strong hydroxyl radical scavenging activity (Guo et al., 2009). It has also been suggested that organic acids present in RJ contribute to antioxidant activity through metal chelation and increase the effect of total polyphenols (Balkanska et al., 2017). The antioxidant activity of phenolic compounds is mainly due to their redox properties, which can play an important role in absorbing and neutralizing free radicals (Javanmardi et al., 2003). Studies have shown that RJ plays an important role in the immune system (Li et al., 2013), reduces blood pressure (Tokunaga et al., 2004) and has antitumor property (Shirzad et al., 2013). Thus, the aim of the present study was to investigate the protective effect of royal jelly in varicocele-induced oxidative damages and disrupts spermatogenesis cycle of rat testis by biochemical and histopathological methods. The present study demonstrates, for the first time, the possible effects of royal jelly on reducing the complications of experimental varicocele in rats.

## 2. Material and methods

### 2.1. Animals and drugs

Twenty-one adult male Wistar albino rats (aged 7–8 weeks) weighting  $200 \pm 50$  g were randomly divided into three groups (Carmignani et al., 1983; Sofikitis et al., 1992; De Stefani et al., 2005; Amirshahi and Najafi, 2013). Group I: Control (healthy rats without induction of varicocele).

Group II: varicocele induction and injection of physiological saline daily with 3 nM solution via subcutaneous injection.

Group III: varicocele induction and treatment with RJ (daily with 200 mg/kg) via gavage directly into the stomach (Nekeety et al., 2007; Amirshahi and Najafi, 2013; Zahmatkesh et al., 2014; Ahmadnia et al.,

2015).

All animal experiments comply with the ARRIVE guidelines and carried out in accordance with the U.K. Animals (Scientific Procedures) Act, 1986 and associated guidelines, EU Directive 2010/63/EU for animal experiments, and were approved by the Ethics Committee of Lorestan University of Medical Sciences.

### 2.2. Experimental procedure

For induction of varicocele, the animals were anaesthetized with Ketamine (Razak, Iran), IP = 60 mg/kg and Xylazine (Trittau, Germany), 1 mg/kg. A vertical midline section with a length of 3–4 mm was created at the abdominal region. After detection of the left renal vein and the insertion point of the internal spermatic vein, 50% of the left ventricular vein was blocked by 20 gauge angio catheter and 4-0 silk suture. The surgery site was closed with 3-0 silk sutures (Ozturk, Koca et al. 2013). All of the surgical procedures were performed under sterile conditions (Köksal, Erdoğan et al. 2002; Bernal, Baldwin et al. 2009). The animals were housed in cages (three or four animals/cage) under controlled temperature ( $22 \pm 2^\circ\text{C}$ ). They had free access to standard diet, tap water and 12 h of light and darkness for five weeks. In this research, the ethical procedures used in animal experimentation were applied. At the end of the experiment (6 weeks after creation of varicocele), all the animals were sacrificed. The abdominal cavity was opened up through a midline abdominal incision and the testes were excised quickly. Half of the testes were fixed by Bouin's fixative (0.2% picric acid/2% (V/V) formaldehyde in PBS2% [V/V]) for histological evaluation (Najafi et al., 2014). The other half was stored for subsequent biochemical assays at  $-70^\circ\text{C}$ .

### 2.3. Antioxidant enzyme activity and MDA level

The testicular tissue samples thawed on ice and homogenized in PBS buffer by homogenizer. The protein content of the testicular tissue was assayed by the Bradford method (Bradford, 1976). This method relies on the attachment of Coomassie Brilliant Blue anionic forms to the arginine and lysine. Tissue catalase activity can be assayed using the procedure proposed by Aebi (Aebi, 1984). The basis of this method is to reduce the light absorbance of H<sub>2</sub>O<sub>2</sub> at 240 nm. The reaction contained 0.1 ml of testicular homogenate, 1.9 ml 50 mM phosphate buffer, pH 7.0 and 1.0 ml of freshly prepared 30% (v/v) hydrogen peroxide (H<sub>2</sub>O<sub>2</sub>). Enzyme activity was expressed as unit's /mg protein (Köksal et al., 2002; Kheradmand et al., 2009; Hanumanth Goud et al., 2012; Asadi et al., 2018). SOD activity was evaluated by the method described by Rukmini (Rukmini et al., 2004). This method was based on the ability of the SOD to inhibit reduction of the nitro-blue tetrazolium. The reaction contained 2.7 ml of 0.067 M phosphate buffer, pH 7.8, riboflavin (0.05 ml of 0.12 mM), as well as nitro-blue tetrazolium (0.1 ml of 1.5 mM), methionine (0.05 ml of 0.01 M) and 0.1 ml of enzyme samples. One unit of SOD is defined as the amount of enzyme required to inhibit the reduction of NBT by 50% under specific conditions. The absorbance was measured at 560 nm. Results were expressed as units (U) of enzyme activity (u/mg protein). GPX was measured based on the Rotruck method (Rotruck et al., 1980). The samples were read at 420 nm and expressed as nmol/mg protein. The reaction contained Tris-HCl buffer (2.0 ml of 0.4 M), pH 7.0, sodium azide (0.01 ml of 10 mM), enzyme (0.2 ml), glutathione (0.2 ml) and H<sub>2</sub>O<sub>2</sub> (0.5 ml of 0.2 mM). The contents were incubated at  $37^\circ\text{C}$  for 10 min. Then, the reaction was terminated by addition of 0.4 ml 10% (v/v) TCA, and was centrifuged at 5000 rpm for five minutes. MDA test was performed using thiobarbituric acid reaction. This method was described as the Esterbauer method (Esterbauer and Zollern, 1989). MDA reacts with thiobarbituric acid to give a red compound that is absorbed at 532 nm in a spectrophotometer (Esterbauer and Cheeseman, 1990; Sohrabipour et al., 2013; Najafi et al., 2014). The absorption level was obtained using the molar coefficient, based on  $\mu\text{mol/mg}$  of protein.

**Table 1**  
Johnsen's score for spermatogenesis assessment.

Score	Histological criteria
10	Full spermatogenesis and perfect tubules
9	Disorganized spermatogenesis; slightly impaired spermatogenesis
8	A few spermatozoa present
7	No spermatozoa but many spermatids present
6	No spermatozoa, only a few spermatids present
5	No spermatozoa or spermatids but many spermatocytes present
4	Only a few spermatocytes present
3	No spermatocytes only spermatogonia present
2	No germ cells but only Sertoli cells present
1	No germ cells and no Sertoli cells present

## 2.4. Histopathological evaluation

The fixed testis tissues were dehydrated in a graded ethanol series of 70–100% and processed for embedding in paraffin. Sections of 5  $\mu$ m obtained were deparaffinised and stained with Hematoxylin-Eosin (H&E). They were examined by Olympus light microscopy (Olympus Optical Co.). For histopathologic damage, a minimum of 5 microscopic areas were selected and about 100 seminiferous tubules were recorded from each animal. The testis sections were graded numerically to assess the degree of histological changes associated with seminiferous tubule injury as previously described by Johnsen (1970). According to this scoring system, the testicular biopsies were further evaluated and given a score from 1 to 10 (Table 1).

## 2.5. Sperm characteristics

To evaluate sperm parameters, the Cauda epididymis was carefully separated from the testis and placed in a Petri dish containing 2 ml of medium (Hams F10) containing 0.5% bovine serum albumin. Epididymis caudal was minced with scissors to release the sperm and was placed in an incubator (37 °C with 5% CO<sub>2</sub>) for 25 min. To count the sperm, the semen was diluted with 1:2 proportion. Approximately, 15  $\mu$ L of the diluted sperm suspension was transferred to each counting chamber of the hemocytometer and all the squares (1–9) were counted. Sperm count and viability were done under a light microscope. Total numbers of motile sperms per 100 sperms were counted. Percentage of sperm viability was accessed by the one step eosin-nigrosine staining technique. Non stained cells were considered as alive and in dead cells, stain had passed through the membrane and colored as orange-red. The sperm heads were counted and expressed as million/ml of suspension.

## 2.6. Data analysis

The statistical analysis was carried out using the SPSS package, version 16.0. The Kolmogorov-Smirnov and the Shapiro-Wilk's test was used to check the normal distribution of data. The differences among the groups were assessed by the analysis of variance (ANOVA) followed by the Duncan test. The results expressed as mean  $\pm$  (S.E.M.) and values of  $P < 0.05$  were considered statistically significant.

## 3. Results

### 3.1. Antioxidant enzyme activity and MDA level

Antioxidants enzyme activity, MDA levels and total antioxidant capacity (TAC) in the three groups are shown in Fig. 1 and 2. Our findings show, untreated varicocelized model (Group II) had a significantly ( $p < 0.05$ ) decrease in CAT ( $0.108 \pm 0.0178$ ), SOD ( $0.160 \pm 0.002$ ), GPx ( $8.425 \pm 0.149$ ) activities and TAC ( $1.16 \pm 0.15$ ). These results indicate that the administration of RJ in

group III significantly ( $p < 0.05$ ) increased activity of CAT ( $0.223 \pm 0.0178$ ), SOD ( $0.177 \pm 0.002$ ), GPx ( $9.575 \pm 0.149$ ) and TAC ( $2.67 \pm 0.15$ ). The activities of these antioxidant enzymes in RJ Group were roughly similar to that of the control values.

Our findings suggest that induction of varicocele can significantly ( $P < 0.05$ ) increased MDA level ( $4.055 \pm 0.219$ ) compared to the control group. In this regard, the administration of royal jelly in group III significantly ( $P < 0.05$ ) reduced MDA levels ( $1.960 \pm 0.219$ ) compared to group II (Fig. 2).

### 3.2. Histopathology

Our finding suggests that in the control Group (I) the testes had normal morphologic characteristics. The seminiferous tubules closely packed and basement membrane were regular (Fig. 3-A). The germ cells were organized in concentric layers when compared to the Group II and Group III testes (Fig. 3-B).

In Group II, there were various multifocal structural changes affecting the seminiferous tubules with loss of their normal architecture with decreased diameters. Widening of the spaces between the seminiferous tubules and atrophic cells in numerous seminiferous tubules can be seen (Fig. 4-A) (arrow). In this group, the basement membrane was thickened and necrosis tubular can be seen (Fig. 4-B). Also it was observed an increase in the histopathological damage score, tubular atrophy and decreases reduction in the the number of germ cells, compared to the control group (Fig. 4-C).

In Group III, the results showed a relatively normal developed histopathological feature (Fig. 5-A). In addition, the RJ exhibited relatively complete spermatogenesis, spermatozoa and decrease in the luminal areas when compared to Group II. However, in some tubules, a decrease in the number of germ cells was observed (Fig. 5-B).

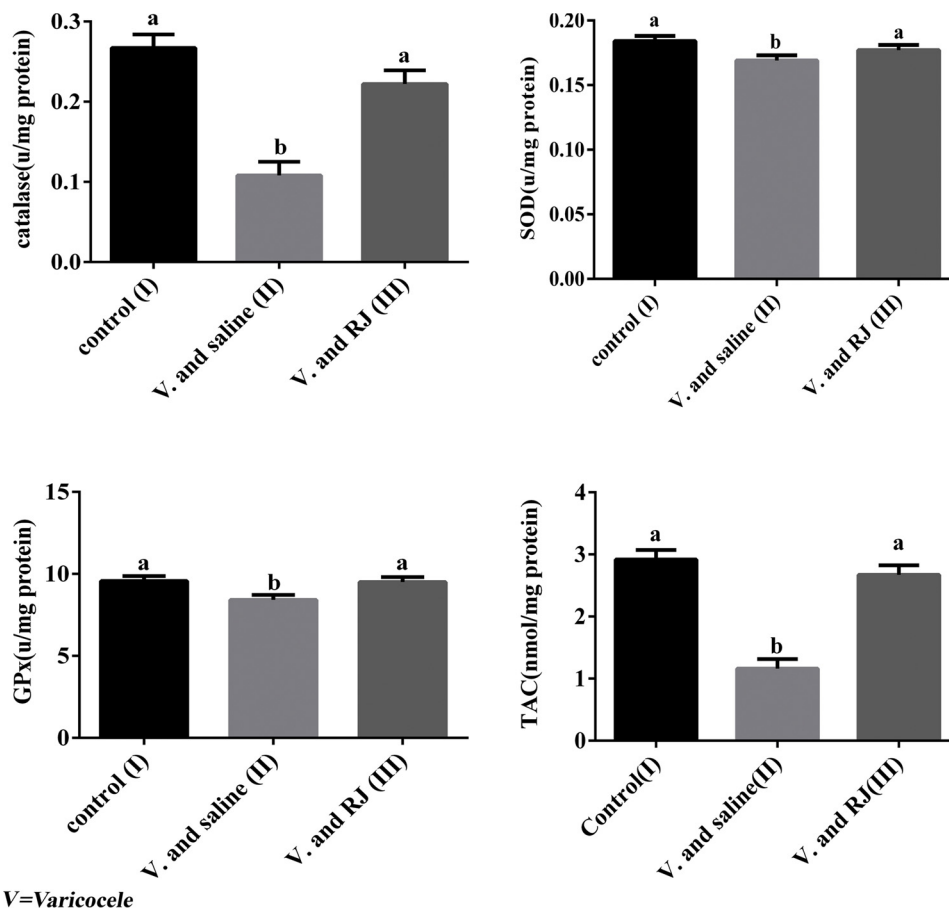
Results of the Johnsen score in Group I (control group) showed a significant ( $p < 0.05$ ) increase in the mean score ( $9.5 \pm 0.814$ ) when compared to Group II and Group III. In Group II, there was a significant ( $p < 0.05$ ) reduction in the mean score ( $6.04 \pm 1.4$ ) when compared to Group I and Group III. Our results showed that in the royal jelly group (Group III), the mean score ( $7.94 \pm 1.5$ ) significantly improved ( $p < 0.05$ ) when compared to Group II (Fig. 6).

### 3.3. Sperm parameters

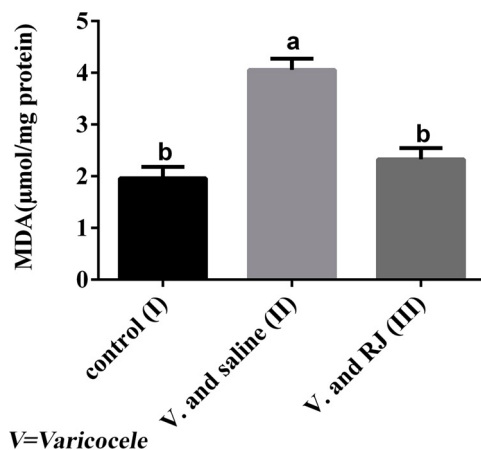
The results of the sperm parameters analysis are depicted in Fig. 7. In Group I, the sperm count and viability significantly increased viability were significantly higher ( $p < 0.05$ ) when compared to Group II and Group III. This shows the deleterious effect of the varicocele on sperm quality. While the administration of 200 mg/kg RJ (III) significantly increased ( $p < 0.05$ ) sperm viability in compared to the varicocele and saline group. In this experiment, RJ administration improved the sperm count. Although, these changes were not significant in compared to saline to the varicocele group (II).

## 4. Discussion

The negative effects of varicocele on fertility are widely recognized. The present study confirms previous studies that the induction of left varicocele in Wistar rats results in a bilateral increase the level of MDA and statistically significant decrease in the level of antioxidant enzymes activities ( $p < 0.05$ ) (Turner, 2001; Semercioz et al., 2003; Asadi et al., 2018). A variety of antioxidants have also been assessed for their ability to counteract oxidative stress caused by varicocele created by alternative mechanisms (Asadi et al., 2018). It seems that RJ protects the testicular tissue against oxidative stress in rats with varicoceles induction. We confirmed that rats with experimental varicocele and supplemented with 200 mg/kg/day of RJ (III) had a significant increase in the antioxidant enzyme activity and testicular content of SOD, CAT, GPx and TAC compared to the group II. These observations are in



**Fig. 1.** Effect of royal jelly on biochemical factors following varicocele induction in Rat. The values are expressed as mean  $\pm$  SEM (n = 7). P values < 0.05 were considered significant. a, b Mean values with the same letter do not differ statistically.



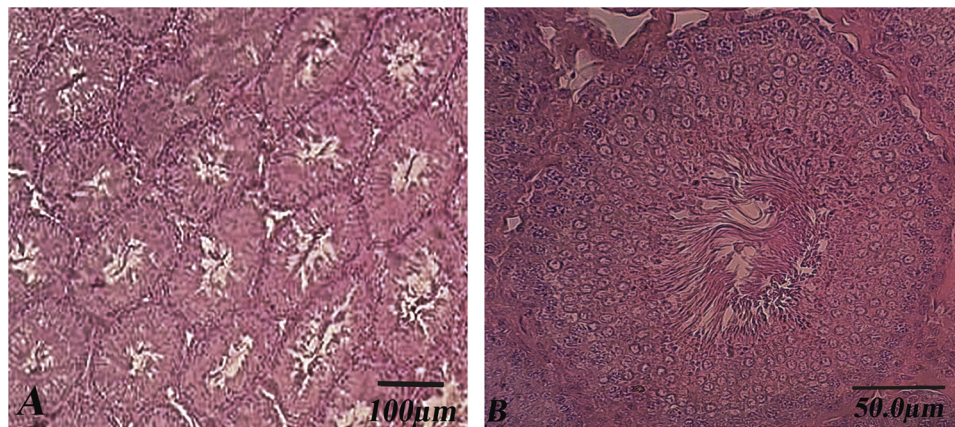
**Fig. 2.** Effect of royal jelly on MDA levels following varicocele induction in Rat. The values are expressed as mean  $\pm$  SEM (n = 7). P values < 0.05 were considered significant. a, b Mean values with the same letter do not differ statistically.

accordance with the outcomes obtained by previous researchers (Nekeety et al., 2007; Hassan, 2009; Silici et al., 2011; Najafi et al., 2014; Zahmatkesh et al., 2014). The three primary antioxidant enzymes, namely CAT, SOD, GPx and TAC contained in the cells were thought to be necessary for life in all oxygen metabolizing cells (Varjovi et al., 2015). The positive effects of RJ antioxidant activities in testes, liver, kidneys, Pancreas, tumor cells, sexual efficiency in adult male rats and sub fertile men are widely recognized (Nekeety et al., 2007;

Amirshahi and Najafi, 2013; Shirzad et al., 2013; Ahmadnia et al., 2015; Nejati et al., 2016). Antioxidant property related to the function of the proteins of RJ caused inhibition of free radical activity (Nagai and Inoue, 2004). More than 29 antioxidant bio peptides were purified from the hydrolysis of RJ proteins. Several mechanisms for the antioxidant properties of RJ have been identified including hydroxyl radical scavenging activity, hydrogen peroxide scavenging activity, metal-chelating activity and superoxide radical scavenging activity (Guo et al., 2009).

The present study indicated that lipid peroxidation (MDA) in testis significantly increased in varicocele rats. While RJ treatment significantly ameliorated the decrease in MDA levels (Decrease by about 50%) in varicocele rats compared to the group II. This result agrees with previous studies which have demonstrated the RJ caused statistically significant decreases in the level of MDA of testis (Hassan, 2009; Najafi et al., 2014; Zahmatkesh et al., 2014), liver and kidney (Cavusoglu et al., 2009; Karadeniz et al., 2011; Silici et al., 2011). Malondialdehyde level is commonly known as a marker of oxidative stress and the antioxidant status in patients with varicocele (Gawel et al., 2004). One of the mechanisms associated with decrease MDA level is related to the vitamins in the royal jelly. The royal jelly contains vitamin C, vitamin E and arginine. Vitamin E and C is a well-documented antioxidant and has been shown to inhibit free-radical induced damage to sensitive cell membranes of the testis and reduced lipid peroxidation in tissue estimation by malondialdehyde (Hassan, 2009). Moreover, vitamin E had a significantly increased activity level of SOD, CAT and GPx and a reduced lipid peroxidation which is evidenced by significant reduction in level of MDA (Saalu et al., 2013). Also in 2009, Guo confirmed that royal jelly proteins (RJPs) hydrolyzed with protease





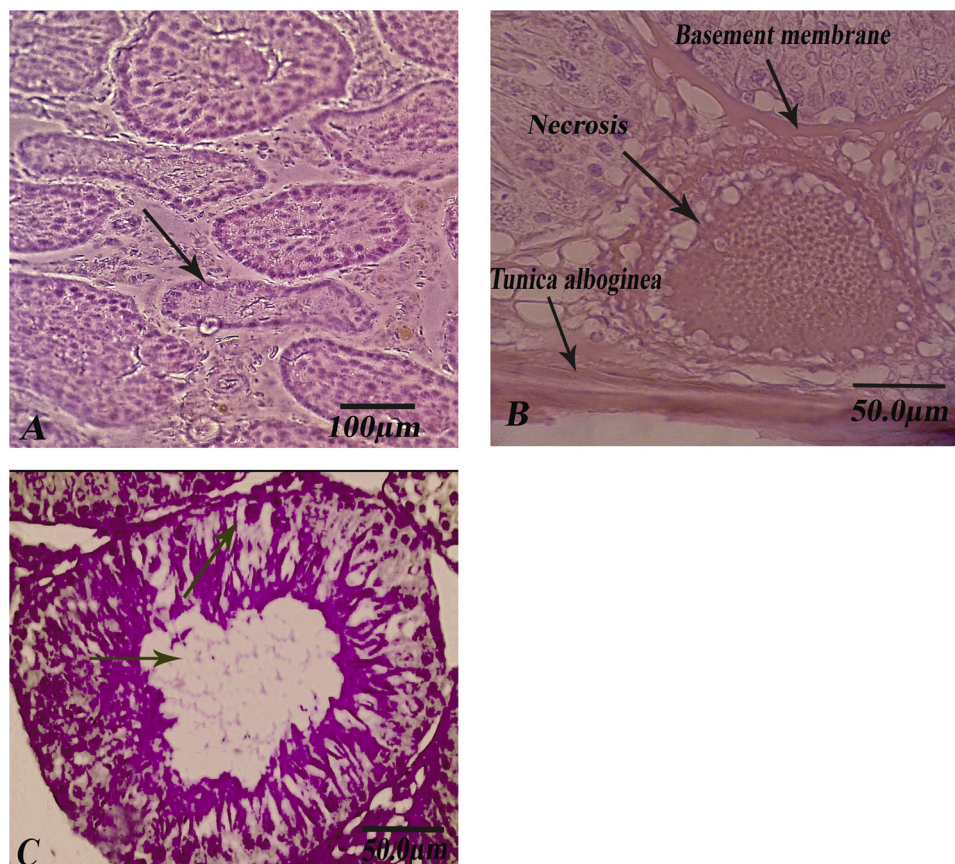
**Fig. 3.** Histological sections of rat testes in the control group.  
A-normal architecture of the seminiferous tubules is seen (H-E, X100).  
B-full spermatogenesis is seen in the seminiferous tubule (H-E, X200).

N show the strong antioxidative activity against the peroxidation of linoleic acid (Guo et al. 2009).

Furthermore, on microscopic examination, histopathologic changes were observed in varicoceles rats. These changes included decrease in tubular diameter, spermatogenic arrest, disorganization, degeneration and decrease in the number of germ cells. While our histological findings showed that RJ administration caused less degenerative alterations in rats with varicoceles induction. These results confirmed the results of other researchers (Karadeniz et al., 2011). It seems that one of the effective factors that lead to smaller histological modifications is the increase in anti-oxidant. Increasing activities of these antioxidant enzymes in the RJ group implied a decrease in the histopathologic changes after varicocele induction reflects the important role that these

enzymes play in scavenging free radicals. Our findings are similar to results of other investigators such as Najafi et al. (Najafi et al., 2014), Zahmatkesh (Zahmatkesh et al., 2014) and Hassan (Hassan, 2009) for testis tissues in which RJ administration caused increase SOD, CAT, GPX and TAC levels. Other reports showed that treatment of diabetic rats with RJ significantly increased CAT activity and improved histological changes in kidney and testis tissues (Ghanbari et al., 2015). Moreover, it was demonstrated that the protein fractions in RJ have high antioxidative activity and scavenging ability against free radicals such as superoxide anion radical, DPPH (1,1- diphenyl-2-picrylhydrazyl) radical, and hydroxyl radical (Nagai and Inoue, 2004; Zahmatkesh et al., 2014).

In the current study, we showed that varicoceles rats had



**Fig. 4.** Histopathological sections of rat testes in the varicocele-saline group.

A-The seminiferous tubules appeared irregular with loss of their normal architecture (H-E, X100).

B-The seminiferous tubule necrosis and the basement membranes appeared to be thickened (H-E, X200).

C- Tubule showed obvious atrophy; spermatogenic cells were significant reduction spermatogenic cells decreased significantly.

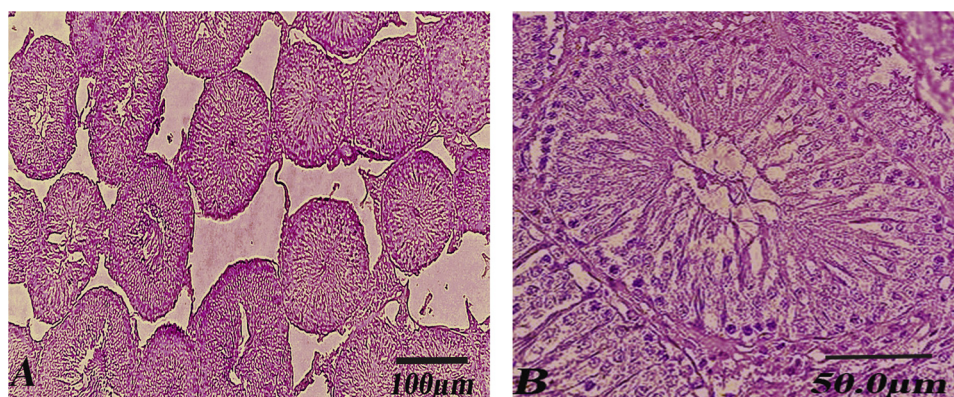


Fig. 5. Histopathological sections of rat testes in the RJ group.

A-Architecture of the seminiferous tubules was relatively normal (H-E, X100).

B-seminiferous tubules appeared with regular outlines and normal lining of the stratified germinal epithelium (H-E, X200).

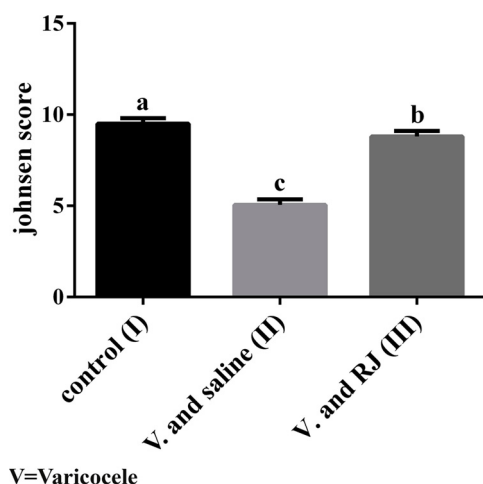


Fig. 6. Effect of royal jelly on Johnsen score following varicocele induction in Rat.

The values are expressed as mean  $\pm$  SEM (n = 7). P values < 0.05 were considered significant.

a, b, c Mean values with the same letter do not differ statistically.

significantly low levels of sperm count and viability compared with the control group. While, treatment with RJ resulted improvement in sperm count and significant increase in sperm viability. These results are agreement with the findings of previous studies (Nekeety et al., 2007;

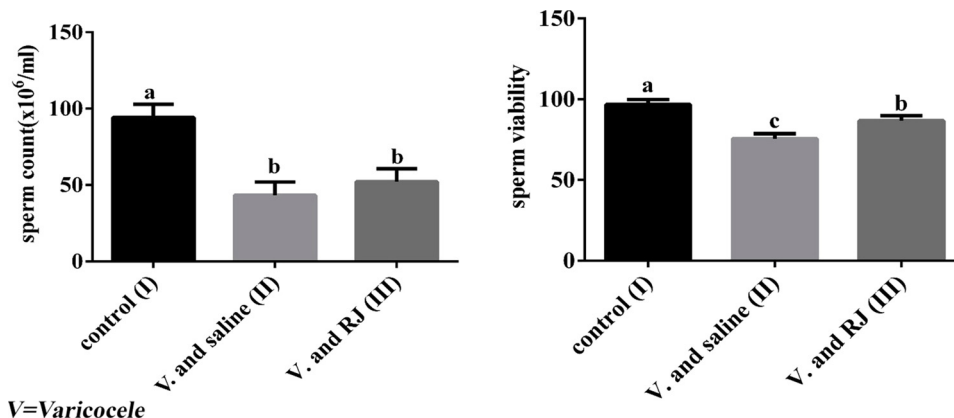


Fig. 7. Effect of royal jelly on sperm parameters following varicocele induction in Rat.

The values are expressed as mean  $\pm$  SEM (n = 7). P values < 0.05 were considered significant.

a, b, c Mean values with the same letter do not differ statistically.

Sanafi et al., 2007; Hassan, 2009; Zahmatkesh et al., 2014; Jalali et al., 2015). One mechanism is that the RJ enhances production of the seminal fluid from the secondary sex organs, which play the main role in sperm's viability and motility (Sanafi et al., 2007). Also, RJ contains acetylcholine, L- arginine and Carnitine amino acids, which helps to stimulate gonadotropin secretion of the hypothalamic level and essential for spermatogenesis (Mitsushima et al., 2008). Moreover the amino acid and fatty acids specific to RJ, especially 10-hydroxy-2-decenoic acid content of RJ may play a role as well by enhancing acrosome reaction, sperm count, sperm viability and improving fertilization (Renard et al., 1996; Comhaire et al., 2000). Another mechanism is that the zinc supplement in royal jelly can increase testosterone levels and increase fertility. Studies confirmed that testosterone is essential for spermatogenesis from spermatogonia to spermatids (Boselli et al., 2003). In the current study, although the sperm count in group III was higher compared with that in groups II, the difference was not significant. It seems that the sample size, effective dose and short-term of RJ administration might have been responsible for the lack of significant difference.

## 5. Conclusion

Varicocele has negative effect on male reproductive system. However, Royal jelly protects rat testis against oxidative stress effects of varicocele. This protection may be due to the enhancement of antioxidant enzymes formation and the suppressive effects of lipid peroxidation and free radical generation. However, further experimentation with higher dosage and long-term for investigating the association



between RJ administration and sperm parameters is warranted.

## Notes

This work was supported by the Razi Herbal Medicine Research Center, Lorestan University of Medical Sciences with the code 200.94.20797, and was carried out with the cooperation of the Biotechnology Division of the Animal Science Research Institute.

## Conflict of interest

The authors declare that they have no conflicts of interest.

## Acknowledgment

This research project was registered with the code number (200.94.20797) at Razi Herbal Medicines Research Center, Lorestan University of Medical Sciences. The authors thank the authorities of Lorestan University of Medical Sciences and Animal Science Research Institute (ASRI) for their cooperation.

## References

- Aebi, H., 1984. Catalase in vitro. *Meth. Enzymol.* 105, 121–126.
- Agarwal, A., Allamaneni, S.S., Nallella, K.P., George, A.T., Mascha, E., 2005. Correlation of reactive oxygen species levels with the fertilization rate after in vitro fertilization: a qualified meta-analysis. *Fertil. Steril.* 84 (1), 228–231.
- Agarwal, A., Hamada, A., Esteves, S.C., 2012. Insight into oxidative stress in varicocele-associated male infertility: part 1. *Nat. Rev. Urol.* 9 (12), 678.
- Agarwal, A., Sharma, R., Harlev, A., Esteves, S.C., 2016. Effect of varicocele on semen characteristics according to the new 2010 World Health Organization criteria: a systematic review and meta-analysis. *Asian J. Androl.* 18 (2), 163.
- Ahmadnia, H., Sharifi, N., Alizadeh, S., Roohani, Z., Kamalati, A., Marjan, S., 2015. Wonderful effects of royal jelly on treatment of male-factor related infertility. *Austin J. Reprod. Med. Infertil.* 2 (6), 1031.
- Amirshahi, T., Najafi, Gh., 2013. Biochemical and histological evaluation of protective effect of royal jelly on pancreas-induced oxidative stress in male rat pancreas. *J. Mazand. Univ. Med. Sci.* 23 (107), 107–115.
- Asadi, N., Kheradmand, A., Gholami, M., Moradi, F.H., 2018. Effect of ghrelin on the biochemical and histopathology parameters and spermatogenesis cycle following experimental varicocele in rat. *Andrologia* 50 (10), e13106.
- Balercia, G., Regoli, F., Armeni, T., Koverech, A., Mantero, F., Boscaro, M., 2005. Placebo-controlled double-blind randomized trial on the use of L-carnitine, L-acetylcarnitine, or combined L-carnitine and L-acetylcarnitine in men with idiopathic asthenozoospermia. *Fertil. Steril.* 84 (3), 662–671.
- Balkanska, R., Marghitas, L.A., Pavel, C.I., 2017. Antioxidant activity and total polyphenol content of royal jelly from Bulgaria. *Int. J. Curr. Microbiol. Appl. Sci.* 6 (10), 578–585.
- Barnutiu, L.I., M. L. Dezmierean, D.S., Mihai, C.M., Bobis, O., 2011. Chemical composition and antimicrobial activity of Royal Jelly-REVIEW. *Anim. Sci. Biotechnol.* 44 (2), 67–72.
- Bernal, J., Baldwin, M., Gleason, T., Kuhlman, S., Moore, G., Talcott, M., 2009. Guidelines for rodent survival surgery. *J. Investig. Surg.* 22 (6), 445–451.
- Boselli, E., Sabatini, C.M., Marazzan, A.G., Lercker, G., 2003. Determination and changes of free amino acids in royal jelly during storage. *Apidologie* 34 (2), 129–137.
- Bradford, M., 1976. A rapid and sensitive method for the quantitation of microgram quantities of protein utilizing the principle of protein-dye binding. *Anal. Biochem.* 72 (1), 248–254.
- Bromfield, E.G., Anderson, A.L., McLaughlin, E.A., Nixon, B., 2015. The impact of oxidative stress on chaperone-mediated human sperm-egg interaction. *Hum. Reprod.* 30 (11), 2597–2613.
- Carmignani, G., Tedde, G., De Stefani, S., Montella, A., Pirozzi-Farina, F., Maffezzini, M., 1983. Experimental varicocele in the rat—a new experimental model. *Urol. Res.* 11 (4), 195–198.
- Cavusoglu, K., Yapar, K., Yalcin, E., 2009. Royal jelly (honey bee) is a potential antioxidant against cadmium-induced genotoxicity and oxidative stress in albino mice. *J. Med. Food* 12 (6), 1286–1292.
- Cho, K.S., Seo, J.T., 2014. Effect of varicolectomy on male infertility. *Korean J. Urol.* 55 (11), 703–709.
- Comhaire, F., Christophe, A., Zalata, A., Dhooze, W., Mahmoud, A., Depuydt, C., 2000. The effects of combined conventional treatment, oral antioxidants and essential fatty acids on sperm biology in subfertile men. *Prostaglandins Leukot. Essent. Fatty Acids (PLEFA)* 63 (3), 159–165.
- De Stefani, S., Silingardi, V., Micali, S., Mofferdin, A., Sighinolfi, M., Celia, A., Bianchi, G., Giulini, S., Volpe, A., Giusti, F., 2005. Experimental varicocele in the rat: early evaluation of the nitric oxide levels and histological alterations in the testicular tissue. *Andrologia* 37 (4), 115–118.
- Di Meo, S., Reed, T.T., Venditti, P., Victor, V.M., 2016. Role of ROS and RNS sources in physiological and pathological conditions. *Oxid. Med. Cell. Longev.* <https://doi.org/10.1155/2016/1245049>.
- Esterbauer, H., Cheeseman, K.H., 1990. Determination of aldehydic lipid peroxidation products: malonaldehyde and 4-hydroxynonenal. *Methods Enzymol.* 186, 407–421.
- Esterbauer, H., Zollner, H., 1989. Methods for determination of aldehydic lipid peroxidation products. *Free Radic. Biol. Med.* 7 (2), 197–203.
- Evers, J.L., Collins, J., 2004. Surgery or embolisation for varicocele in subfertile men. *Cochrane Database Syst. Rev.* (3).
- Evers, J.H.L., Collins, J., Clarke, J., 2008. Surgery or embolisation for varicoceles in subfertile men. *Cochrane Database Syst. Rev.* (3).
- Gawel, S., Wardas, M., Niedworok, E., Wardas, P., 2004. Malondialdehyde (MDA) as a lipid peroxidation marker. *Wiadomosci lekarskie (Warsaw, Poland: 1960)* 57 (9–10), 453–455.
- Ghanbari, E., Nejati, V., Azadbakht, M., 2015. Protective effect of royal jelly against renal damage in Streptozotocin induced diabetic rats. *Iran. J. Toxicol.* 9 (28), 1258–1263.
- Guo, H., Kouzuma, Y., Yonekura, M., 2009. Structures and properties of antioxidative peptides derived from royal jelly protein. *Food Chem.* 113 (1), 238–245.
- Hanumanth Goud, G., Ravindra, M.A., Jayalakshmi, S., Sreeramulu, K., 2012. Inhibition of catalase isozymes of *Helicoverpa armigera* (Lepidoptera: noctuidae) by salicylic acid. *IOSR J. Pharm. Biol. Sci. (IOSRJPBS)* 3 (2), 26–28.
- Hassan, A., 2009. Effect of royal jelly on sexual efficiency in adult male rats. *Iraqi J. Vet. Sci.* 23, 155–160.
- Jalali, A., Najafi, G., Hosseini, M.R., Sedighnia, A., 2015. Royal Jelly alleviates sperm toxicity and improves in vitro fertilization outcome in Stanazolol-treated mice. *Iran. J. Rep. Med.* 13 (1), 15–22.
- Javanmardi, J., Stushoff, C., Locke, E., Vivanco, J., 2003. Antioxidant activity and total phenolic content of Iranian *Ocimum* accessions. *Food Chem.* 83 (4), 547–550.
- Johnsen, S.G., 1970. Testicular biopsy score count—a method for registration of spermatogenesis in human testes: normal values and results in 335 hypogonadal males. *Hormone Res. Pediatrics* 1 (1), 2–25.
- Karadeniz, A., Simsek, N., Karakus, E., Yildirim, S., Kara, A., Can, I., 2011. Royal jelly modulates oxidative stress and apoptosis in liver and kidneys of rats treated with cisplatin. *Oxid. Med. Cell. Longev.* 1–10.
- khatri, D.K., Juvekar, A., 2013. Preliminary phytochemical and antioxidant evaluation of a polyherbal formulation. *Int. J. Phytopharm.* 4 (5), 322–328.
- Kheradmand, A., Alirezaei, M., Asadian, P., Rafiei Alavi, E., Joorabi, S., 2009. Antioxidant enzyme activity and MDA level in the rat testis following chronic administration of ghrelin. *Andrologia* 41 (6), 335–340.
- Köksal, T., Erdoğan, T., Toptaş, B., Gülkesen, K.H., Usta, M., Baykal, A., Baykara, M., 2002. Effect of experimental varicocele in rats on testicular oxidative stress status. *Andrologia* 34 (4), 242–247.
- Li, Xa, Huang, C., Xue, Y., 2013. Contribution of lipids in honeybee (*Apis mellifera*) royal jelly to health. *J. Med. Food* 16 (2), 96–102.
- Mahbobi, A., Woyke, J., Abbasi, S., 2012. Effects of the age of grafted larvae and the effects of supplemental feeding on some morphological characteristics of Iranian queen honey bees (*Apis mellifera* meda Skorikov). *J. Apic. Sci.* 56 (1) 93–80.
- Mitsushima, D., Takeke, K., Funabashi, T., Kimura, F., 2008. Gonadal steroid hormones maintain the stress-induced acetylcholine release in the hippocampus: simultaneous measurements of the extracellular acetylcholine and serum corticosterone levels in the same subjects. *Endocrinology* 149 (2), 802–811.
- Nagai, T., Inoue, R., 2004. Preparation and the functional properties of water extract and alkaline extract of royal jelly. *Food Chem.* 84 (2), 181–186.
- Najafi, G., Nejati, V., Jalali, A.S., Zahmatkesh, E., 2014. Protective role of royal jelly in oxymetholone-induced oxidative injury in mouse testis. *Iran. J. Toxicol.* 8 (25).
- Nakajima, Y., Tsuruma, K., Shimazawa, M., Mishima, S., Hara, H., 2009. Comparison of bee products based on assays of antioxidant capacities. *Complement. Altern. Med.* 9 (1), 1–9.
- Nejati, V., Zahmatkesh, E., Babaei, M., 2016. Protective role of royal jelly in Oxymetholone-induced oxidative injury in mouse testis. *Iran. J. Toxicol.* 20 (4), 229–234.
- Nekeety, A.A., Kholy, W., Abbas, N.F., Ebaid, A., Amra, H.A., Abdel-Wahhab, M.A., 2007. Efficacy of royal jelly against the oxidative stress of fumonisin in rats. *Toxicol.* 50 (2).
- Oliva, A., Dotta, A., Multigner, L., 2009. Pentoxifylline and antioxidants improve sperm quality in male patients with varicocele. *Fertil. Steril.* 91 (4), 1536–1539.
- Ozturk, M.I., Koca, O., Keles, M.O., Haklar, G., Baykan, O., Ercan, F., Tok, O.E., Karaman, M.I., 2013. The impact of unilateral experimental rat varicocele model on testicular histopathology, Leydig cell counts, and intratesticular testosterone levels of both testes. *Urol. J.* 10 (3), 973–980.
- Pastuszek, A.W., Wang, R., 2015. Varicocele and testicular function. *Asian J. Androl.* 17 (4), 659.
- Renard, P., Grizard, G., Griveau, J.-F., Sion, B., Boucher, D., Le Lannou, D., 1996. Improvement of motility and fertilization potential of post thaw human sperm using glutamine. *Cryobiology* 33 (3), 311–319.
- Rotruck, J., Pope, A., Ganther, H., Swanson, A., Hafeman, D., Hoekstra, W., 1980. Selenium: biochemical role as a component of glutathione peroxidase. *Nutr. Rev.* 38 (8), 280–283.
- Rukmini, M., D'souza, B., D'souza, V., 2004. Superoxide dismutase and catalase activities and their correlation with malondialdehyde in schizophrenic patients. *Indian J. Clin. Biochem.* 19 (2).
- Saalu, L., Akunna, G., Ogunmodede, O., 2013. Evidences for deleterious role of free radicals in experimental varicocele using animal model. *Br. J. Med. Med. Res.* 3 (4), 1125.
- Sanafi, A.E., Mohssin, S., Abdulla, S.M., 2007. Effect of royal jelly on male infertility. *Thi-Qar Med. J.* 1 (1), 1–12.
- Semercioz, A., Onur, R., Ogras, S., Orhan, I., 2003. Effects of melatonin on testicular tissue nitric oxide level and antioxidant enzyme activities in experimentally induced

- left varicocele. *Neuroendocrinol. Lett.* 24 (1/2), 86–90.
- Shirzad, M., Kordyazdi, R., Shahinfard, N., Nikokar, M., 2013. Does Royal jelly affect tumor cells. *J. Herb. Med. Pharmacol.* 2 (2), 45–48.
- Silici, S., Ekmekcioglu, O., Kanbur, M., Deniz, K., 2011. The protective effect of royal jelly against cisplatin-induced renal oxidative stress in rats. *World J. Urol.* 29 (1), 127–132.
- Smith, R., Kaune, H., Parodi, D., Madariaga, M., Ríos, R., Morales, I., 2006. Increased sperm DNA damage in patients with varicocele: relationship with seminal oxidative stress. *Hum. Reprod.* 21 (4), 986–993.
- Sofikitis, N., Takahashi, C., Nakamura, I., Hirakawa, S., Miyagawa, I., 1992. Surgical repair of secondary right varicocele in rats with primary left varicocele: effects on fertility, testicular temperature, spermatogenesis, and sperm maturation. *Arch. Androl.* 28 (1), 43–52.
- Sohrabipour, S., Jafari, A., Kamalinejad, M., Sarrafnejad, A., Shahrestany, T., Sadeghipour, H.R., 2013. The role of flaxseed and vitamin E on oxidative stress in prepubertal rats with experimental varicocele: an experimental study. *Iran. J. Reprod. Med.* 11 (6), 459.
- Tokunaga, K.-h., Yoshida, C., Suzuki, K.-m., Maruyama, H., Futamura, Y., Araki, Y., 2004. Antihypertensive effect of peptides from royal jelly in spontaneously hypertensive rats. *Biol. Pharm. Bull.* 27 (2), 189–192.
- Turner, T., 2001. The study of varicocele through the use of animal models. *Hum. Reprod. Update* 7 (1), 78–84.
- Varjovi, M.B., Valizadeh, M., Bandehagh, A., 2015. Primary antioxidant enzymes and their important role in oxidative stress in plants and mammalian. *Biol. Forum-Int. J.* 7 (2), 148–154.
- Wong, W.Y., Merkus, H.M., Thomas, C.M., Menkveld, R., Zielhuis, G.A., Steegers-Theunissen, R.P., 2002. Effects of folic acid and zinc sulfate on male factor sub-fertility: a double-blind, randomized, placebo-controlled trial. *Fertil. Steril.* 77 (3), 491–498.
- Zahmatkesh, E., Najafi, G., Nejati, V., Heidari, R., 2014. Protective effect of royal jelly on the sperm parameters and testosterone level and lipid peroxidation in adult mice treated with oxymetholone. *Avicenna J. Phytomed.* 4 (1), 43.